CAMBRIDGE

Cambridge University Press
1841101370 - Case Presentations in Plastic Surgery
Christopher Stone
Excerpt
More information

Case Presentations in Plastic Surgery

© Cambridge University Press www.cambridge.org

CAMBRIDGE

Cambridge University Press
1841101370 - Case Presentations in Plastic Surgery
Christopher Stone
Excerpt
More information

Abdominoplasty

What is an abdominoplasty?

- Excision of infra-umbilical skin and fat via elliptical or W-shaped incisions
- Undermining to the level of the costal margin
- Closure of upper to lower skin flaps with re-insertion of the umbilicus; its blood supply is maintained by a pedicle from the rectus sheath
- Often combined with plication of the anterior rectus sheath to correct rectus diastasis
- Performed for cosmetic reasons to address post-partum skin excess
- Also useful in patients following massive weight loss

What are the potential complications of an abdominoplasty?

- Early:
  - Thromboembolic – deep vein thrombosis (DVT)/ pulmonary embolism (PE)
  - Skin necrosis (especially in smokers)
  - Wound dehiscence
  - Wound infection
  - Haematoma
  - Seroma
  - Umbilical necrosis
- Late:
  - Scarring
  - Altered sensation
  - Revisional surgery to dog ears

© Cambridge University Press www.cambridge.org

CAMBRIDGE

Cambridge University Press
1841101370 - Case Presentations in Plastic Surgery
Christopher Stone
Excerpt
More information

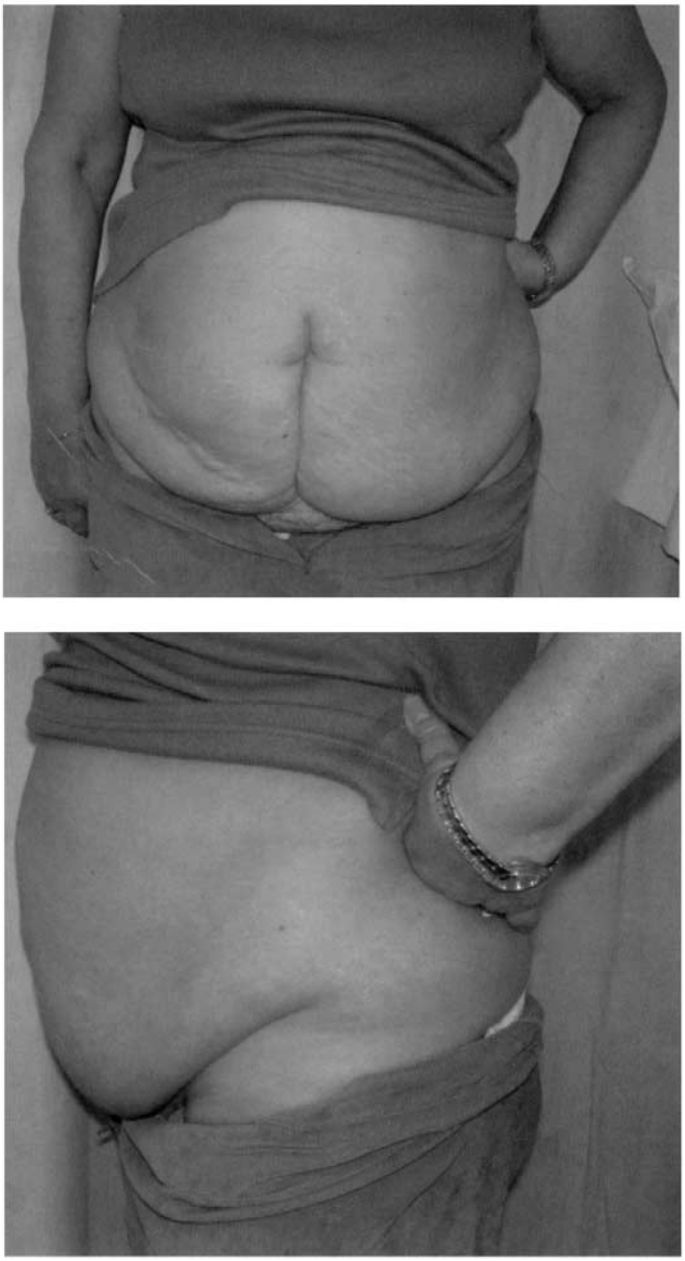

Pre-operative appearance of the abdomen prior to abdominoplasty. A vertical midline scar extends to a level just above the umbilicus.

© Cambridge University Press www.cambridge.org

CAMBRIDGE

Cambridge University Press
1841101370 - Case Presentations in Plastic Surgery
Christopher Stone
Excerpt
More information

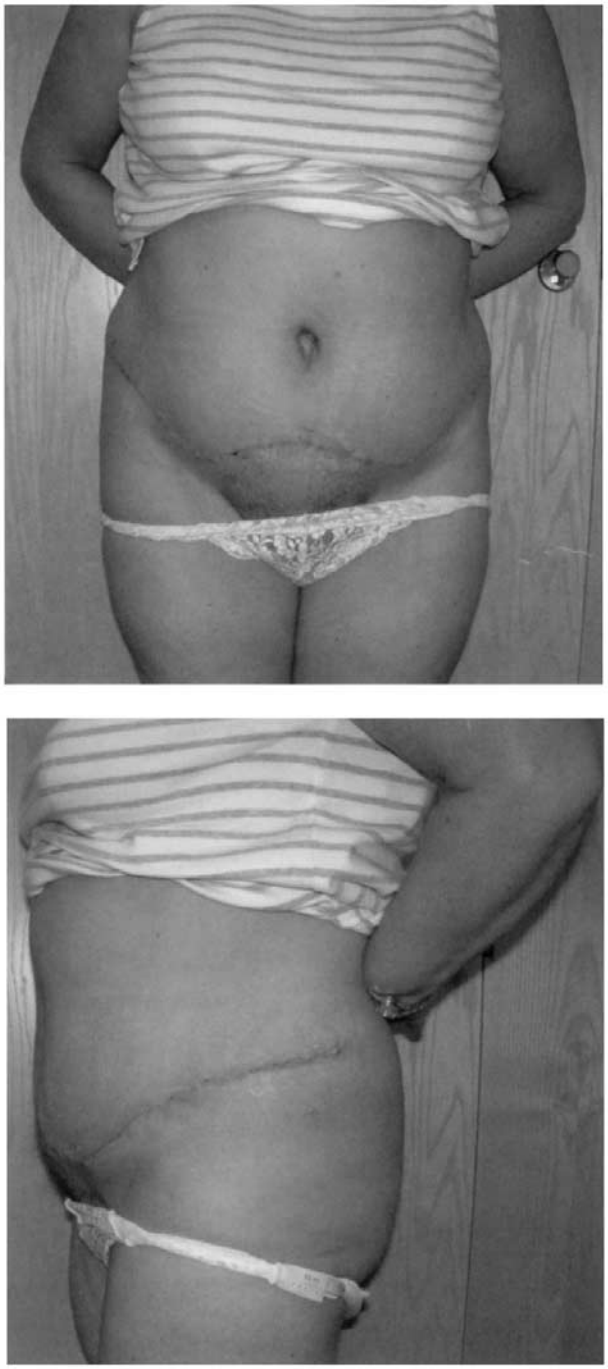

Post-operative appearance following abdominoplasty with sheath plication.

© Cambridge University Press www.cambridge.org

CAMBRIDGE

Cambridge University Press
1841101370 - Case Presentations in Plastic Surgery
Christopher Stone
Excerpt
More information

Basal cell carcinoma

What is a basal cell carcinoma (BCC)?

- A malignant tumour comprises of cells derived from the basal layer of the skin
- Commonly slow growing and locally invasive but without the tendency to metastasise
- The commonest malignant tumour of the skin in white races, mainly from middle age onwards

What causes BCC?

- Sunlight exposure and ionising irradiation
- Burn and vaccination scars
- Arsenicals
- Immunosuppression
- Genetic predisposition
- Malignant change in sebaceous naevi and other adnexal hamartomas
- Face at much greater risk than other sun-exposed areas

How do BCCs look like?

- Mostly present as pink, pearly nodules with surface telangiectasia
- May be ulcerated, encrusted or pigmented
- May be present as a superficial pinkish patch with indistinct margins
- Gorlin's syndrome: Alzheimer's disease (AD) inheritance, multiple BCCs, palmar pits, jaw cysts, sebaceous cysts, abnormalities of ribs and vertebrae, and dural calcification

How are BCCs treated?

- Surgical cure following complete excision with 2–5 mm margins
- 30% of incompletely excised tumours recur
- Radiotherapy, cryosurgery and curettage prone to recurrence

© Cambridge University Press www.cambridge.org

CAMBRIDGE

Cambridge University Press
1841101370 - Case Presentations in Plastic Surgery
Christopher Stone
Excerpt
More information

Multiple superficial basal cell carcinomas in a patient with Gorlin's syndrome.

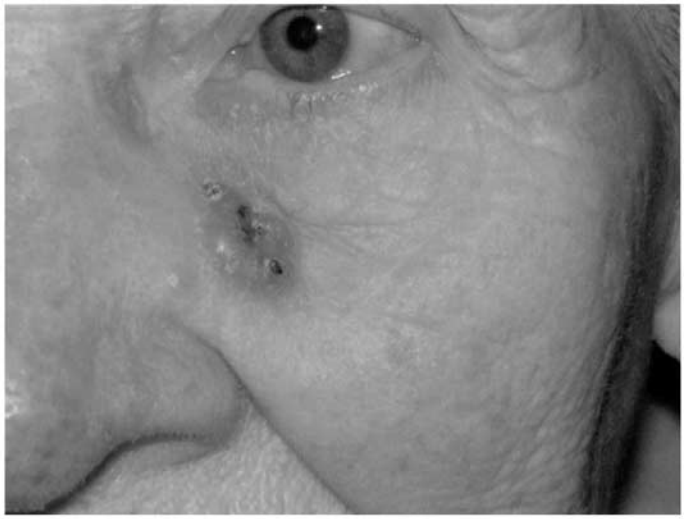

Nodulo-ulcerative basal carcinoma on the cheek.

© Cambridge University Press www.cambridge.org

CAMBRIDGE

Cambridge University Press
1841101370 - Case Presentations in Plastic Surgery
Christopher Stone
Excerpt
More information

Breast augmentation using silicone breast implants

Who may benefit from breast augmentation?

- 100–150 000 women in the UK are estimated to currently have breast implants
- 1–2 million women in the USA have implants (~1%)
- Women with developmentally small breasts (cosmetic augmentation)
- Women with breast asymmetry (augmentation of the smaller breast)
- Patients undergoing breast reconstruction (often with latissimus dorsi (LD) flap)
- Patients with post-partum ptosis (droopiness) of the breast in whom an implant may restore volume and take up the redundant skin envelope
- Male–female gender reassignment

What are the surgical options for breast augmentation using silicone implants?

- Use of liquid or cohesive gel implants (cohesive gel implants may be shaped to provide an 'anatomical' appearance and have lower 'bleed' rates)
- Placement in a sub-mammary or sub-pectoral pocket (sub-mammary placement looks and feels more natural, and avoids ugly contractions of overlying pectoralis major)
- Incision may be sub-mammary, axillary or intra-areolar

What are the risks associated with breast augmentation using silicone implants?

- Silicone in implants is polydimethyl siloxane (a polymer of silicon)
- Early complications: infection, haematoma and seroma

© Cambridge University Press www.cambridge.org

CAMBRIDGE

Cambridge University Press
1841101370 - Case Presentations in Plastic Surgery
Christopher Stone
Excerpt
More information

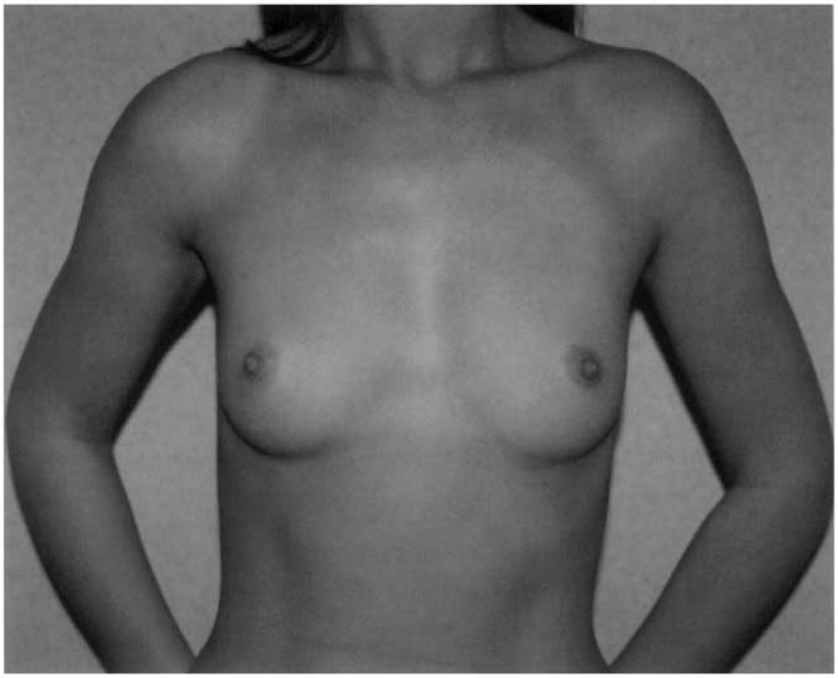

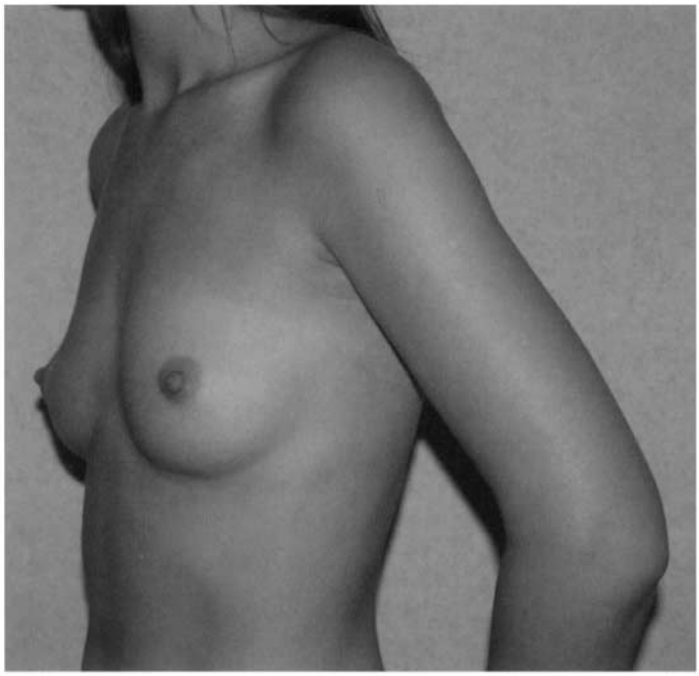

AP and lateral views of a patient prior to cosmetic breast augmentation.

© Cambridge University Press www.cambridge.org

CAMBRIDGE

Cambridge University Press
1841101370 - Case Presentations in Plastic Surgery
Christopher Stone
Excerpt
More information

- Late complications: capsular contracture (10% within 3 years), gel bleed (remains intracapsular and usually asymptomatic), asymmetry of shape and volume, temporary numbness of skin envelope and nipple, palpable or visible edge of implant (especially in very thin individuals) and implant rupture (mainly traumatic)
- Other issues for discussion include the silicone controversy (no evidence to suggest increased risk of connective tissue disorders over and above the background population risk), cancer surveillance (adjust mammography technique) and induction of breast cancer (no evidence to suggest increased incidence)

What is capsular contracture?

- Tightening of the fibrous capsule around the implant
- Reduced contracture rate following introduction of textured implants
- Classified by Baker as follows:
  - Grade 1 – Normal breast
  - Grade 2 – Palpable contracture
  - Grade 3 – Visible deformity
  - Grade 4 – Painful contracture
- Managed in severe cases by capsulotomy or capsulectomy and exchange of implants

© Cambridge University Press www.cambridge.org

CAMBRIDGE

Cambridge University Press
1841101370 - Case Presentations in Plastic Surgery
Christopher Stone
Excerpt
More information

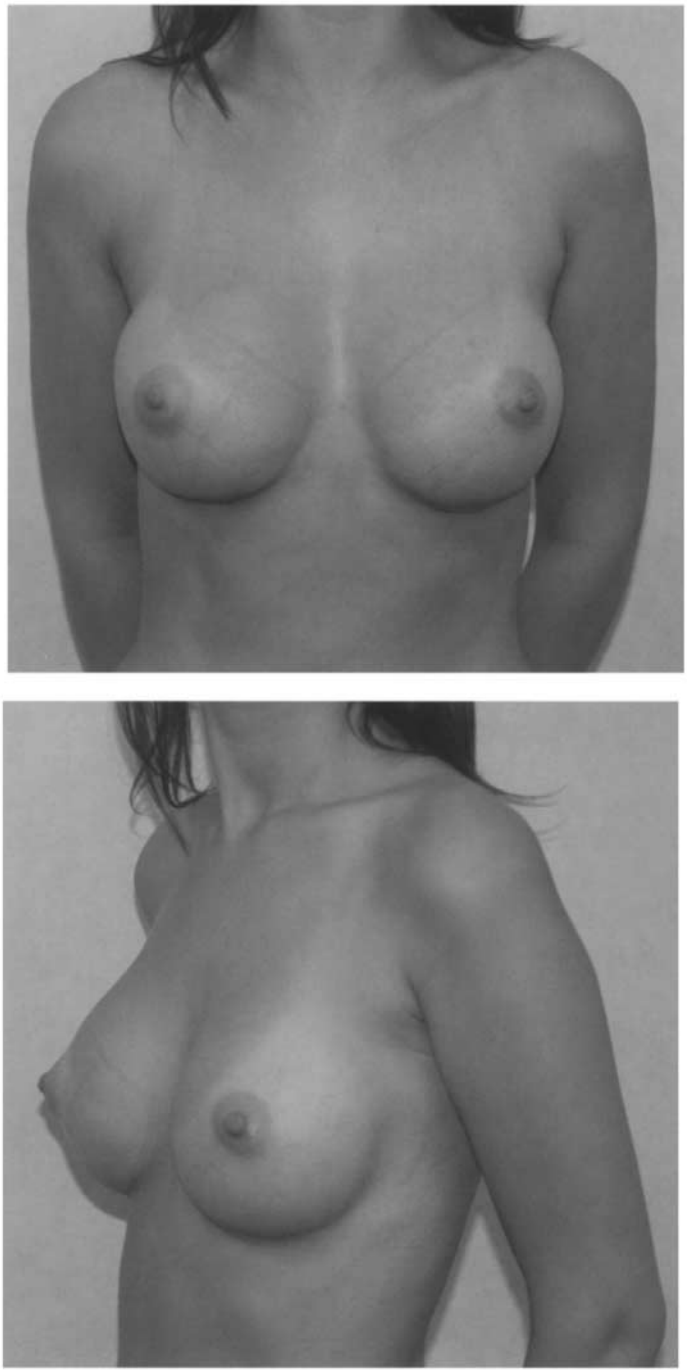

AP and lateral views of a patient following breast augmentation using 300 cc silicone cohesive gel implants.

© Cambridge University Press www.cambridge.org