1 NORMAL HISTOLOGY AND METAPLASIAS

Thomas J. Lawton, MD

ANATOMY AND HISTOLOGY

The female breast is composed of a branching duct system, which begins at the nipple with the major lactiferous ducts and ends with the terminal ductal-lobular unit (TDLU). The nipple is covered by stratified squamous epithelium that focally extends into the major lactiferous ducts (Figure 1.1). Beyond that, the major lactiferous ducts in the region of the nipple are lined by a columnar or cuboidal epithelium with an underlying myoepithelial layer and surrounding basement membrane; this epithelial histology extends to the TDLU. In the nipple area, the major lactiferous ducts have a characteristic "serrated" appearance within a more dense stroma, which, when seen in biopsy specimens, can confirm the lesion biopsied is in the region of the nipple (Figure 1.2).

More distal to this, the branching duct system terminates in the TDLU (Figure 1.3). Here, numerous acini comprise a lobule, which directly connects to the terminal duct. Each acinus is surrounded by basement membrane, upon which a layer of myoepithelial cells and luminal epithelial cells lie (Figure 1.4A). Myoepithelial cells, which often have cleared cytoplasm, can be recognized on H&E alone; their presence can be confirmed by immunohistochemistry with a variety of markers, including smooth muscle myosin heavy chain, calponin, and p63, among others (Figure 1.4B). Lobular development does not occur in the normal male breast.

A variety of physiologic changes occur in the female breast during stages of development, pregnancy, and menopause. One of the more common is lactational change, which occurs in association with pregnancy. The typical histology is that of lobular expansion in which the acini become dilated and the cells within have cleared or vacuolated cytoplasm (Figure 1.5A). The nuclei can become enlarged and may have small nucleoli (Figure 1.5B). Similar changes have been reported in patients who are not or have not been pregnant; the term "pseudolactational change" or "pregnancy-like change" is warranted in these situations. With menopause and the associated decrease in estrogen, the lobules in the female breast can undergo atrophy. Typically, the number and size of lobules decrease, and often a thickening of the basement membrane is noted (Figure 1.6).

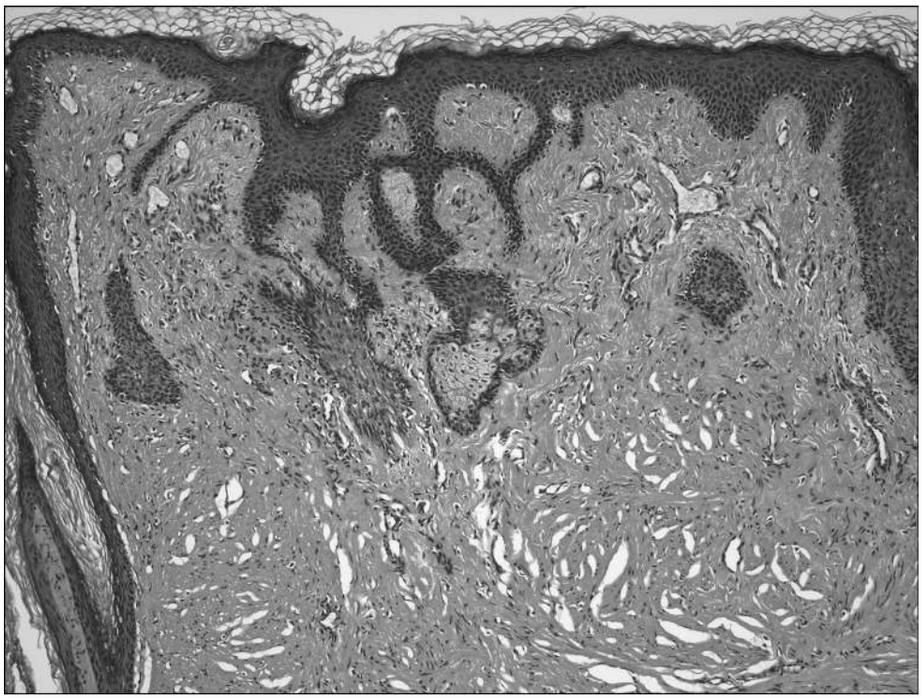

Figure 1.1. Section of nipple showing stratified squamous epithelium and densely fibrotic dermis.

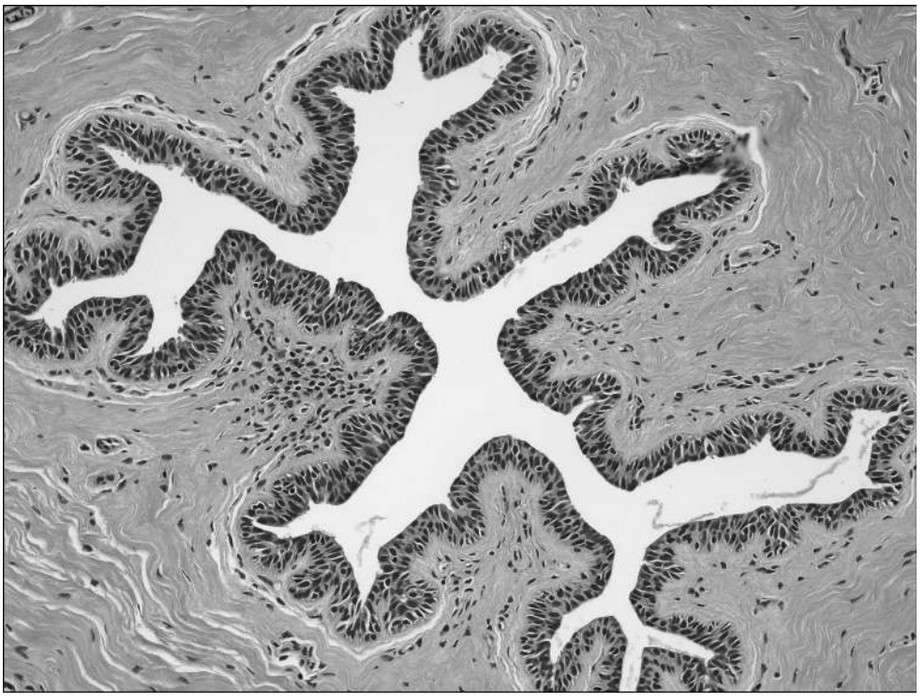

Figure 1.2. Serrated appearance of a major lactiferous duct.

METAPLASIAS

The epithelium of the breast can undergo metaplasia, the most common type being apocrine metaplasia (Figures 1.7A,B). The cells of apocrine metaplasia have a

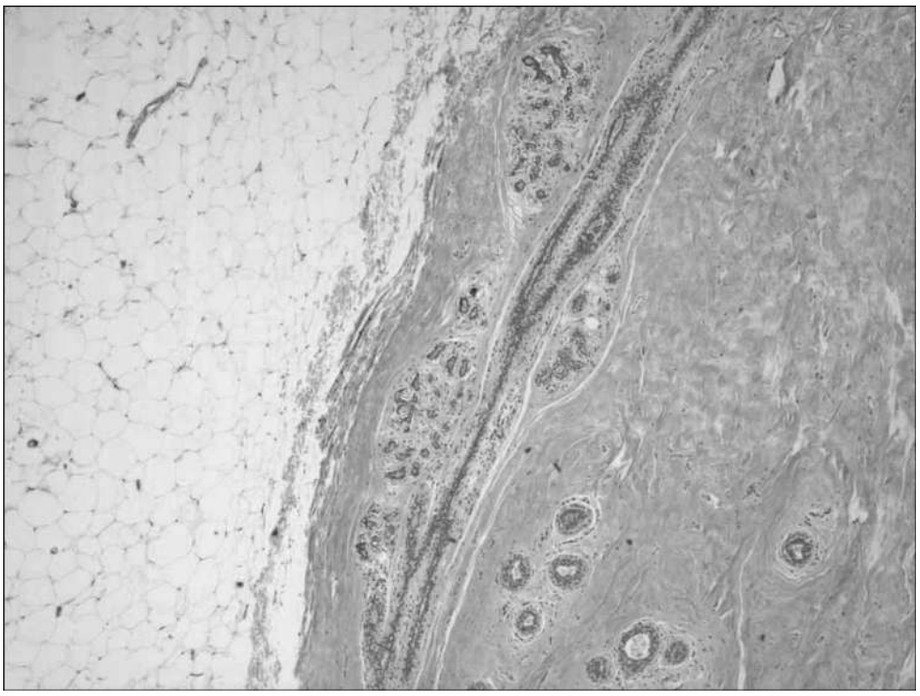

Figure 1.3. Normal breast parenchyma composed of adipose and fibroglandular tissue. The terminal ductal-lobular unit (TDLU) is present.

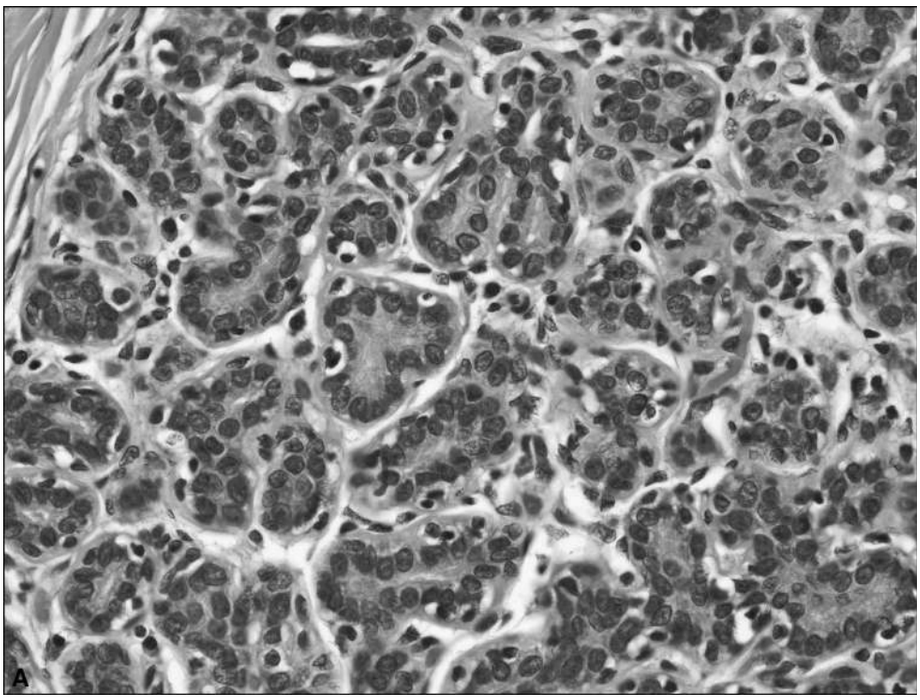

Figure 1.4. (A) High-power view of the acini present in a normal lobule. Note the dark-staining epithelium and the underlying myoepithelial cells with clear cytoplasm.

characteristic appearance with abundant eosinophilic cytoplasm and round to oval nuclei with a single prominent nucleolus. Apocrine metaplasia frequently is seen lining cysts but also can be present in more proliferative lesions, and frequently an architecture with micropapillary formation is seen. Although more complex in

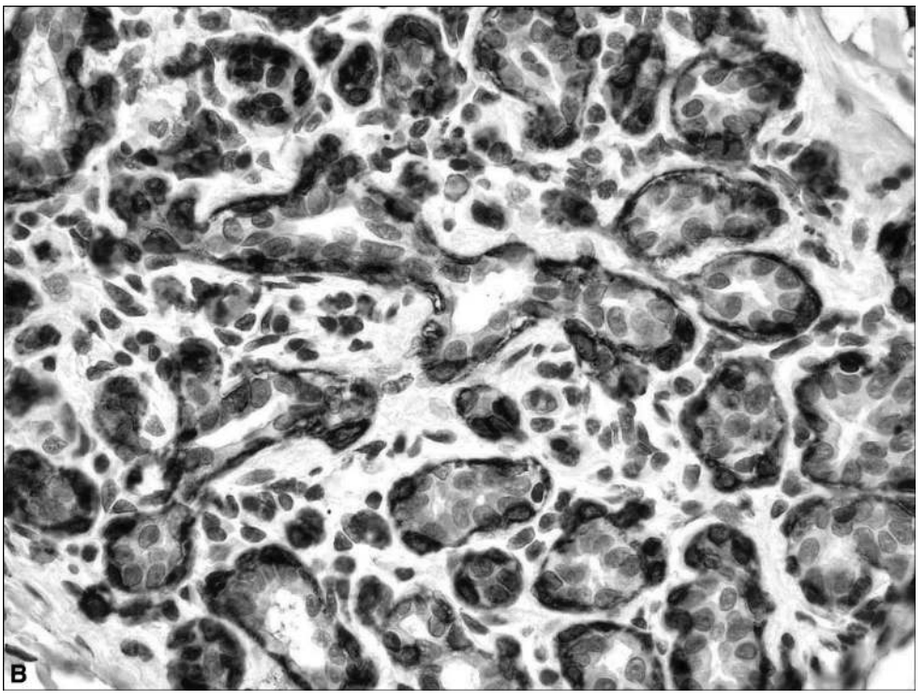

Figure 1.4. *(continued)* (B) Calponin immunostain highlighting the myoepithelial cell layer in the lobule.

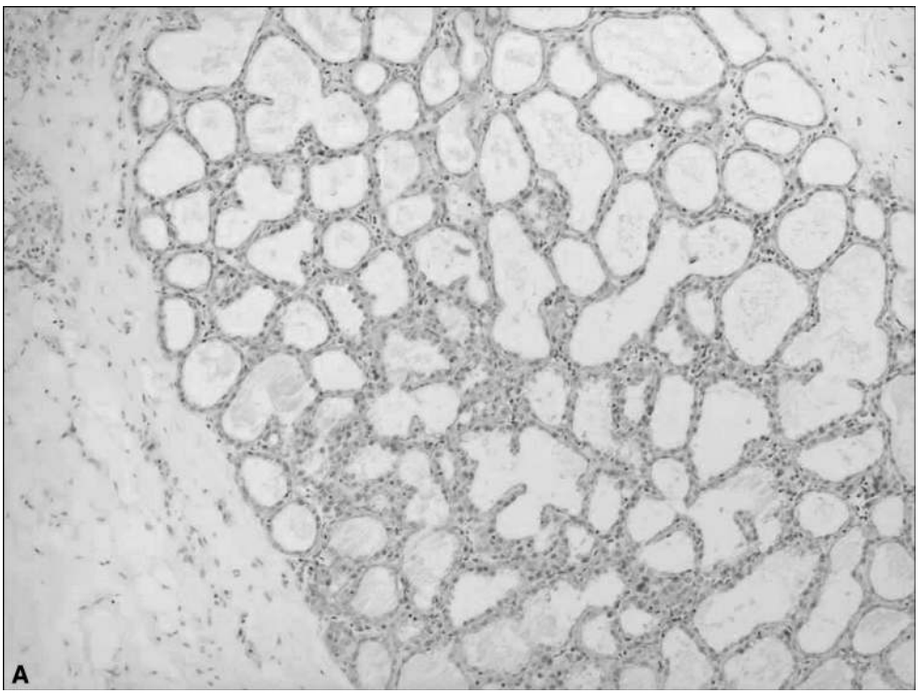

Figure 1.5. (A) Medium-power view of lactational change with an expanded lobule composed of dilated acinar units with luminal secretions. (B) High-power view of lactational change showing the characteristic vacuolated cytoplasm and enlarged nuclei with luminal secretion.

architecture, the cells maintain their uniform appearance. The diagnosis of atypia within apocrine metaplasia is a controversial one, although most authors feel that the presence of nuclear pleomorphism as well as complex architecture is required for a diagnosis of atypia and/or carcinoma in apocrine lesions (Figure 1.7C).

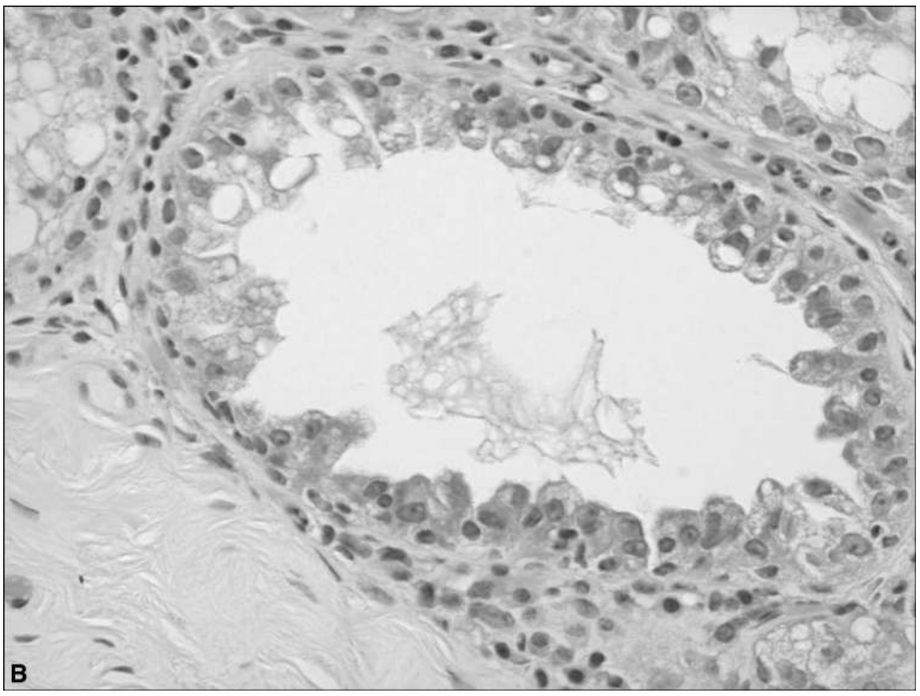

Figure 1.5. *(continued)*

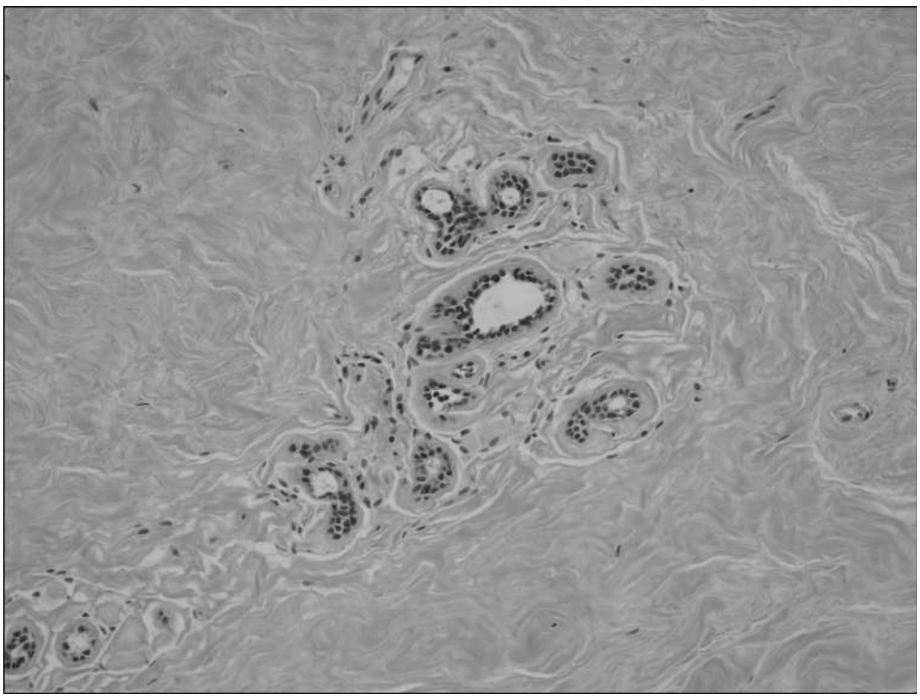

Figure 1.6. Postmenopausal breast with reduced acinar units and thickened basement membranes.

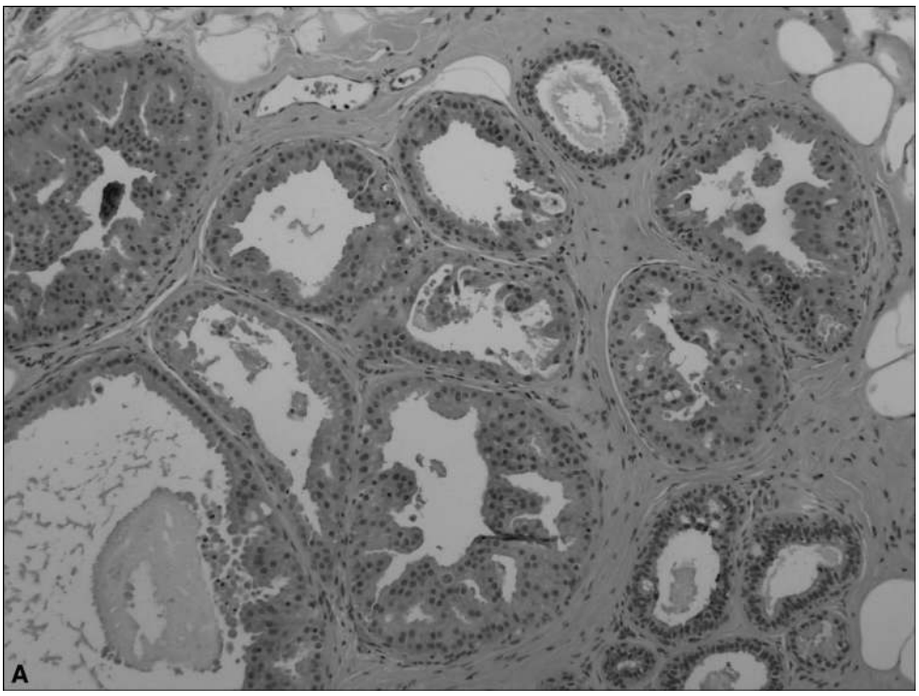

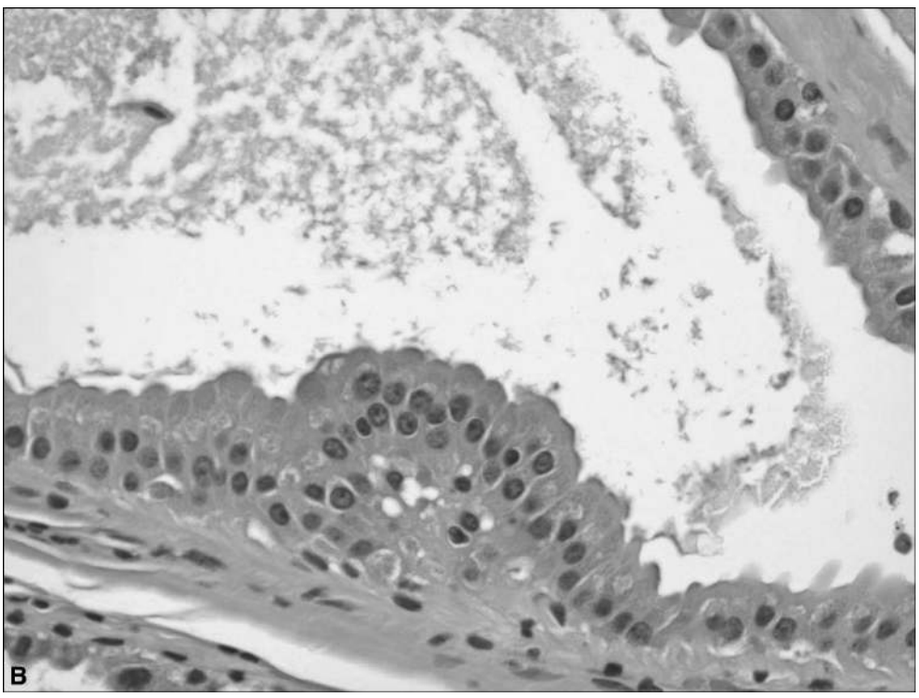

Figure 1.7. (A) Apocrine metaplasia with a micropapillary appearance. (B) Uniform cytology of apocrine metaplasia with eosinophilic cytoplasm and round to oval nuclei with single prominent nucleoli. (C) Apocrine atypia. The proliferation is growing in a more solid pattern, and there is marked nuclear pleomorphism in the lower part of the picture.

Other, less common, metaplasias involving the TDLU include clear cell metaplasia and myoid metaplasia. In clear cell metaplasia, the involved cells have abundant clear cytoplasm with small, dark, almost pyknotic-like nuclei (Figure 1.8). The most important differential is carcinoma in situ with clear

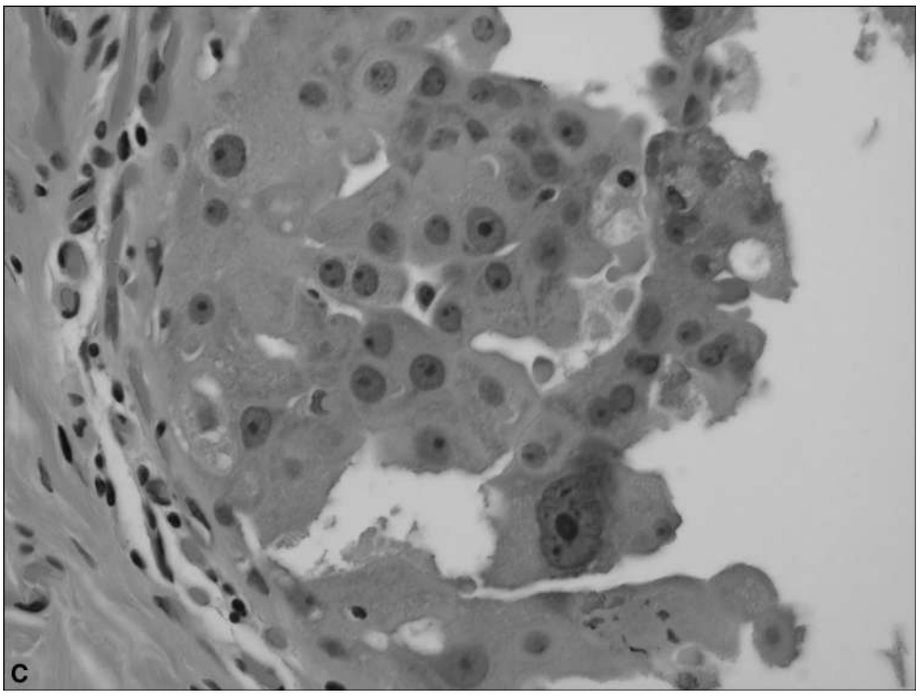

Figure 1.7. *(continued)*

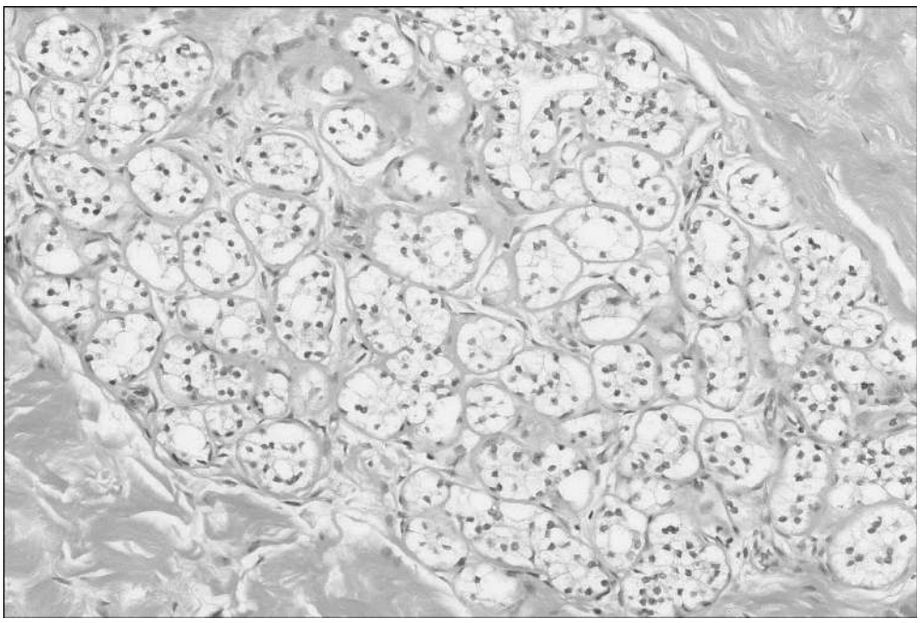

Figure 1.8. Clear cell change in a lobule. The cells have a characteristic cleared out cytoplasm and nuclei that are small and dark.

cell features involving a lobule. Generally, this is not a difficult distinction, and the absence of a clear cell in situ carcinoma elsewhere in the specimen and the bland cytology of the cells can confirm the diagnosis of clear cell metaplasia. In myoid metaplasia, the myoepithelial cells have a more pronounced

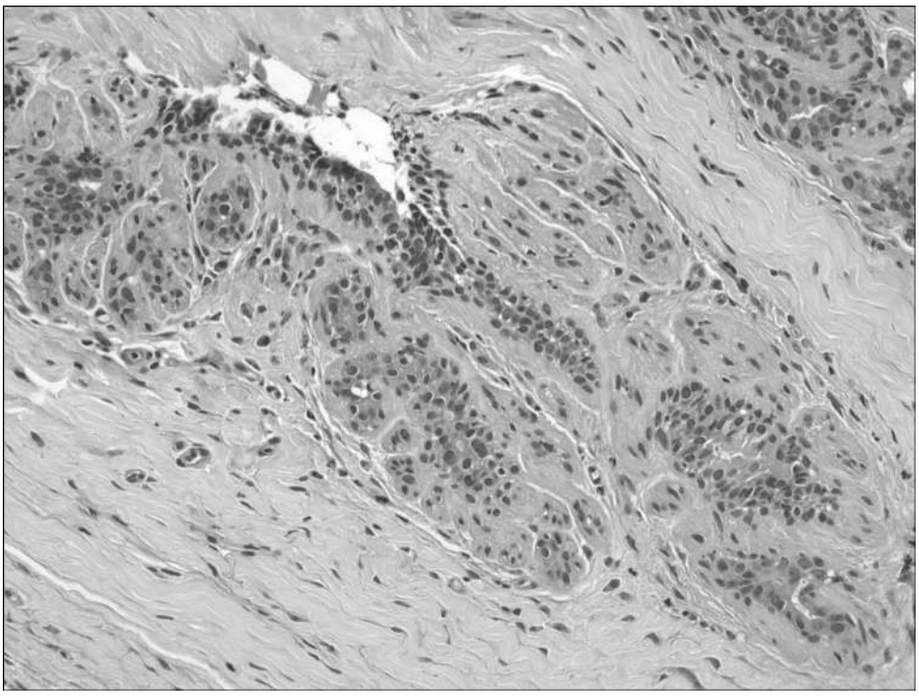

Figure 1.9. Myoid metaplasia. Note the pronounced pink myoepithelial cells with a prominent muscle-like appearance.

spindled appearance; their myoepithelial nature can be confirmed by immunohistochemistry (Figure 1.9).

REFERENCES

Barwick, K. W., M. Kashgarian, et al. (1982). "'Clear-cell' change within duct and lobular epithelium of the human breast." *Pathol Annu* 17(Pt. 1): 319–28.

Battersby, S. and T. J. Anderson (1989). "Histological changes in breast tissue that characterize recent pregnancy." *Histopathology* 15(4): 415–19.

Going, J. J. and T. J. Mohun (2006). "Human breast duct anatomy, the 'sick lobe' hypothesis and intraductal approaches to breast cancer." *Breast Cancer Res Treat*.

Lazard, D., X. Sastre, et al. (1993). "Expression of smooth muscle-specific proteins in myoepithelium and stromal myofibroblasts of normal and malignant human breast tissue." *Proc Natl Acad Sci USA* 90(3): 999–1003.

Love, S. M. and S. H. Barsky (2004). "Anatomy of the nipple and breast ducts revisited." *Cancer* 101(9): 1947–57.

Mills, S. E. and R. E. Fechner (1980). "Focal pregnancy-like change of the breast." *Diagn Gynecol Obstet* 2(1): 67–70.

Moffat, D. F. and J. J. Going (1996). "Three dimensional anatomy of complete duct systems in human breast: pathological and developmental implications." *J Clin Pathol* 49(1): 48–52.

O'Malley, F. P. and A. Bane (2008). "An update on apocrine lesions of the breast." *Histopathology* 52(1): 3–10.

Rusby, J. E., E. F. Brachtel, et al. (2007). "Breast duct anatomy in the human nipple: three-dimensional patterns and clinical implications." *Breast Cancer Res Treat* 106(2): 171–9.

Selim, A. G. and C. A. Wells (1999). "Immunohistochemical localisation of androgen receptor in apocrine metaplasia and apocrine adenosis of the breast: relation to oestrogen and progesterone receptors." *J Clin Pathol* 52(11): 838–41.

Seltzer, V. (1994). "The breast: embryology, development, and anatomy." *Clin Obstet Gynecol* 37(4): 879–80.

Shin, S. J. and P. P. Rosen (2000). "Pregnancy-like (pseudolactational) hyperplasia: a primary diagnosis in mammographically detected lesions of the breast and its relationship to cystic hypersecretory hyperplasia." *Am J Surg Pathol* 24(12): 1670–4.

Stirling, J. W. and J. A. Chandler (1976). "The fine structure of the normal, resting terminal ductal-lobular unit of the female breast." *Virchows Arch A Pathol Anat Histol* 372(3): 205–26.

Tavassoli, F. A. and H. J. Norris (1994). "Intraductal apocrine carcinoma: a clinicopathologic study of 37 cases." *Mod Pathol* 7(8): 813–18.

Tavassoli, F. A. and I. T. Yeh (1987). "Lactational and clear cell changes of the breast in nonlactating, nonpregnant women." *Am J Clin Pathol* 87(1): 23–9.

Viacava, P., A. G. Naccarato, et al. (1997). "Apocrine epithelium of the breast: does it result from metaplasia?" *Virchows Arch* 431(3): 205–9.

Vilanova, J. R., R. Simon, et al. (1983). "Early apocrine change in hyperplastic cystic disease." *Histopathology* 7(5): 693–8.

Vina, M. and C. A. Wells (1989). "Clear cell metaplasia of the breast: a lesion showing eccrine differentiation." *Histopathology* 15(1): 85–92.

2 ADENOSIS, SCLEROSING LESIONS, AND MISCELLANEOUS BENIGN ENTITIES

Thomas J. Lawton, MD

ADENOSIS AND SCLEROSING ADENOSIS

Adenosis and sclerosing adenosis are benign proliferative processes affecting the terminal ductal-lobular unit. Frequently, they are asymptomatic and found on breast imaging because of associated calcifications, but sometimes mass lesions can be formed in which the terms nodular adenosis, adenosis tumor, or tumoral adenosis are often used.

Adenosis refers to a relative increase in the number of acinar units in a lobule. Sclerosing adenosis refers to a similar process in which extensive sclerosis compresses and distorts the acinar units into angulated glands that can give the process an infiltrative appearance (Figure 2.1A). However, at low power a "lobular" circumscribed architecture is maintained. At higher power, myoepithelial cells and surrounding basement membranes can frequently be seen confirming the noninvasive nature of the process (Figure 2.1B). Often, with extensive sclerosis, it can be difficult to see the myoepithelial layer, but the immunostains for myoepithelium (e.g., p63, smooth muscle myosin heavy chain, calponin) can help confirm their presence. It is important not to overdiagnose invasive carcinoma, particularly on core needle biopsy where the edge of the lesion and the circumscribed lobular nature of the process may be difficult to visualize (Figure 2.1C). Frequently, adenosis and sclerosing adenosis form coalesced nodules that may present as a mass. In these situations, the term nodular adenosis, or adenosis tumor, can be used (Figures 2.2A–D).

Apocrine adenosis refers to apocrine metaplasia involving sclerosing adenosis. The characteristic pattern of sclerosing adenosis is present but the epithelial population is replaced by apocrine metaplastic cells (Figure 2.3A). Again, this process can be mistaken for invasive carcinoma, particularly on core needle biopsy and immunohistochemistry can be useful in difficult situations (Figures 2.3B,C).