

Illustrated pathology of

THE SPLEEN

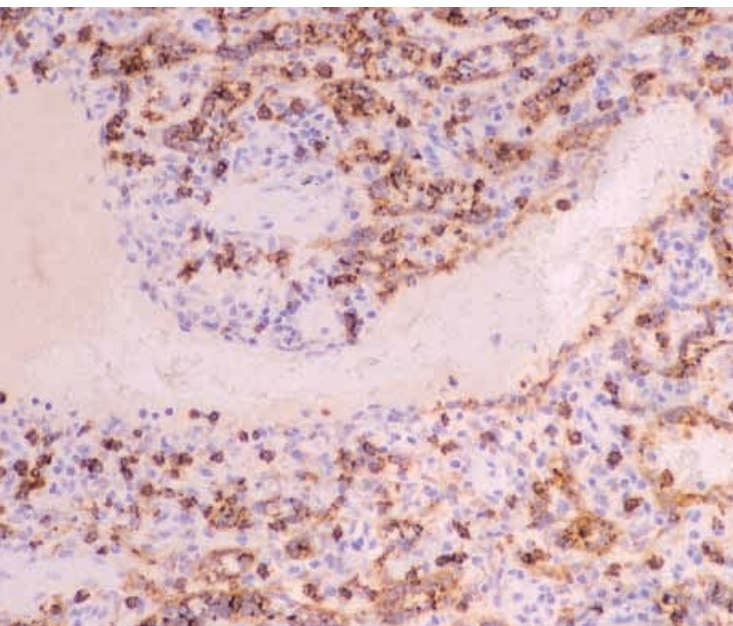
Bridget S. Wilkins

Senior Lecturer
Department of Microbiology and Pathology
University of Southampton, UK

and

Dennis H. Wright

Emeritus Professor of Pathology
University of Southampton, UK



CAMBRIDGE
UNIVERSITY PRESS

PUBLISHED BY THE PRESS SYNDICATE OF THE UNIVERSITY OF CAMBRIDGE
The Pitt Building, Trumpington Street, Cambridge, United Kingdom

CAMBRIDGE UNIVERSITY PRESS

The Edinburgh Building, Cambridge CB2 2RU, UK <http://www.cup.cam.ac.uk>
40 West 20th Street, New York, NY 10011-4211, USA <http://www.cup.org>
10 Stamford Road, Oakleigh, Melbourne 3166, Australia
Ruiz do Alarcón 13, 28014 Madrid, Spain

© Bridget S. Wilkins & Dennis H. Wright 2000

This book is in copyright. Subject to statutory exception and to the provisions of relevant collective licensing agreements, no reproduction of any part may take place without the written permission of Cambridge University Press.

First published 2000

Printed in the United Kingdom at the University Press, Cambridge

Typeface Utopia 9/13pt. *System* QuarkXPress [s e]

A catalogue record for this book is available from the British Library

Library of Congress Cataloguing in Publication data

ISBN 0 521 62227 1 hardback

Every effort has been made in preparing this book to provide accurate and up-to-date information which is in accord with accepted standards and practice at the time of publication. Nevertheless, the authors, editors and publisher can make no warranties that the information contained herein is totally free from error, not least because clinical standards are constantly changing through research and regulation. The authors, editors and publisher therefore disclaim all liability for direct or consequential damages resulting from the use of material contained in this book. The reader is strongly advised to pay careful attention to information provided by the manufacturer of any drugs or equipment that they plan to use.

Contents

	Preface	ix
	Acknowledgements	xi
1	Introduction	1
	Why is splenectomy performed?	1
	Why is splenic pathology perceived to be difficult?	3
	What does the surgeon or physician want from the pathologist?	5
	What information does the pathologist require?	6
	How can fixation and processing be optimized to give the best possible histology?	7
	Ancillary investigations	9
	Splenic biopsy, fine needle aspiration and laparoscopic splenectomy	10
	Implications of splenectomy for the patient	11
	Summary	12
	References	12
2	Normal structure, development and functions of the spleen	13
	Anatomy and vascular supply	13
	Normal micro-anatomy of the spleen	14
	Development of the spleen during embryonic and fetal life	17
	Functional correlates of red and white pulp structure	19
	Abnormalities of splenic function	23
	Hyposplenism	24
	Hypersplenism	25

An immunohistochemical inventory of the spleen	27
References	31

3 Post-traumatic and incidentally removed spleens 35

Introduction	35
Spleens removed incidentally and those removed following trauma are different	35
An approach to analysis of traumatized or incidental splenectomy specimens	37
Reactive changes in individual compartments of the spleen	40
Spontaneous rupture of the spleen	43
References	44

4 The spleen in hereditary blood cell abnormalities and auto-immune disorders 47

Introduction	47
Vaccination before splenectomy	48
Sickle cell anaemia and thalassaemias	49
Hereditary spherocytosis and auto- immune blood cell destruction	51
The nature of HS, AIHA and ITP	52
Macroscopic appearances of the spleen in HS, AIHA and ITP	53
Red pulp	54
White pulp	55
Felty's syndrome	56
Systemic lupus erythematosus	57
Polyarteritis nodosum	59
References	59

5 The spleen in immunodeficiency and systemic infections 63

Inherited immunodeficiency syndromes	63
Acquired immunodeficiency due to drugs or irradiation	65

	Acquired immunodeficiency syndrome and the spleen	66
	Systemic infections involving the spleen in immunocompetent individuals	70
	References	74
6	Lymphomas involving the spleen	77
	Introduction	77
	B cell small lymphocytic lymphoma/chronic lymphocytic leukaemia (B-CLL)	78
	B-prolymphocytic leukaemia	82
	Mantle cell lymphoma (MCL)	82
	Follicle centre cell lymphoma	85
	Splenic marginal zone lymphoma	87
	Lymphoplasmacytoid lymphoma/immunocytoma	91
	Hairy cell leukaemia	92
	Large B cell lymphomas	95
	T cell prolymphocytic leukaemia	96
	Large granular lymphocyte leukaemia, T cell and NK cell types	97
	Splenic T cell lymphoma with erythrophagocytosis	100
	Hepatosplenic $\gamma\delta$ T cell lymphoma	100
	Hodgkin's disease	101
	Nodular lymphocyte and histiocyte predominant Hodgkin's disease (nodular L&H HD)	105
	References	106
7	The spleen in myeloproliferative disorders	111
	Splenic extramedullary haemopoiesis	111
	Systemic mastocytosis	117
	Transient abnormal myelopoiesis in association with Trisomy 21 (Down's syndrome)	121
	The spleen in acute myeloid and lymphoblastic leukaemias	122
	References	122

8 Pathology of the splenic stroma 125

Splenic granulomas	125
Storage disorders involving cordal macrophages	126
Langerhans' cell histiocytosis	136
Splenic pseudotumours and true stromal tumours	137
Peliosis of the spleen	141
Splenic vascular hyalinosis	144
Portal hypertension and the spleen	144
Splenic infarction	145
Gamna–Gandy bodies	147
References	147

9 Metastases and miscellaneous conditions 151

Appearances and primary origins of metastatic cancers involving the spleen	151
Hamartomas	152
Splenic cysts and false cysts	153
Amyloidosis	154
Congenital anomalies of splenic size, number or anatomical position	155
Splenunculi and splenosis	156
Splenic atrophy and fibrosis	157
Peri-splenitis ('sugar-icing' of the spleen)	159
Autolysis in splenic tissue	160
References	161

10 Summary: some key points in splenic differential diagnosis 163

Introduction	163
Reactive spleen or neoplastic lymphoid proliferation?	163
Granulomas and cordal macrophage disorders	173
Extramedullary haemopoiesis – is it significant or not?	176
References	177

Index 181



Introduction

Why is splenectomy performed?

Splenectomy is frequently incidental, performed because of technical necessity in gaining adequate surgical access to the stomach, left side of the colon, left kidney or aorta. Under these circumstances, there may be no distinctive pathology present related to the primary cause for surgery. However, such spleens may not be absolutely normal, and it can be difficult to decide with confidence what are acceptable secondary reactive changes and what might constitute significant co-existent splenic pathology.

Splenectomy may also be performed primarily for therapy. This is obviously the case when the spleen is ruptured following abdominal trauma, a potentially life-threatening situation. It is important to know that splenectomy may none the less be delayed for hours or even days following the traumatic event, since haemorrhage from a damaged spleen does not always occur immediately after the injury, may be minor, or may cause relatively slow development of an intra-abdominal haematoma. Even after a delay of a few hours following the initial injury, changes may be present in the spleen as a response to the injury. Since, in some cases, splenic rupture may follow mild trauma because the organ is abnormal, it is important to know whether any changes present are the result, or part of the cause, of splenic injury.

Splenectomy of a primarily therapeutic

nature is also performed for hypersplenism, most commonly because of excessive red cell destruction in auto-immune haemolytic anaemia (AIHA) or platelet destruction in idiopathic thrombocytopenic purpura (ITP). In ITP, the spleen is often a source of anti-platelet antibody production so that splenectomy also reduces the underlying auto-immune response. Spleens enlarged for a variety of unrelated reasons may also become hyperfunctional in destruction of peripheral blood cells and require removal for control of cytopenias.

Splenectomy for control of symptoms (pain, abdominal swelling) may be performed in any condition giving rise to a massively enlarged spleen, with or without hypersplenism. Examples include myelofibrosis and other chronic myeloproliferative disorders, in which splenectomy also serves the useful purpose of removing a considerable bulk of neoplastic haemopoietic tissue. It is debatable whether or not splenectomy carries a significant risk of removing a major source of productive, normal haemopoiesis in such patients.

Removal of the predominant site of disease involvement may be achieved by splenectomy in certain lymphomas, particularly splenic marginal zone lymphoma/splenic lymphoma with villous lymphocytes. Despite bone marrow and blood involvement in most of these patients, long-term partial or complete remission can be achieved in many by splenectomy. The procedure may also be of value to confirm the precise diagnosis in other patients with known lymphomas in whom splenomegaly is prominent and the precise classification is in doubt.

Splenectomy may be performed primarily for diagnostic purposes when there is unexplained enlargement or unexplained focal pathology such as a cyst or a solid tumour. Associated with many different pathologies underlying such changes, there may be hypersplenism or, less often, hyposplenism.

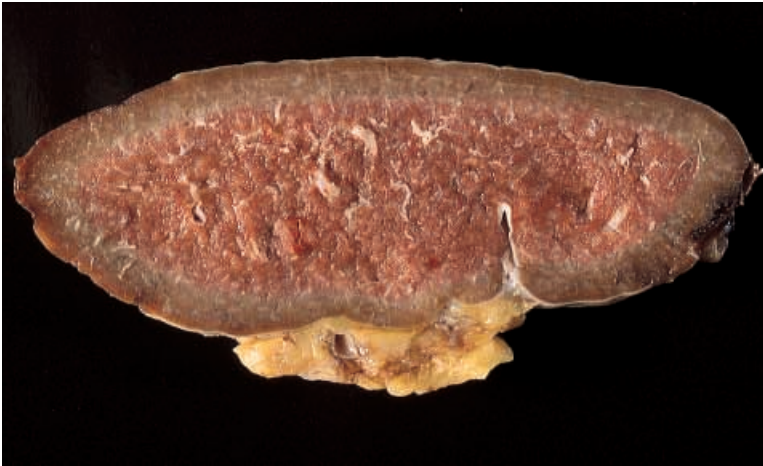

Fig. 1.1. Slice of spleen showing the effects of partial fixation following immersion of the intact organ in formalin for 24 hours. Subcapsular tissue is reasonably well fixed to a depth of approximately 5 mm in this example, but the central parenchyma remains unfixed.

Fig. 1.2. Slice of spleen, similar to that in Fig. 1.1, showing the effects of further fixation for 24 hours after slicing, the spleen having been received unsliced, immersed in formalin. There is a clear line of demarcation between the original zone of fixation and the area of secondary fixation. Histology from the central area would be suboptimal, despite now appearing fixed.



Where the spleen has been removed primarily for diagnostic or therapeutic purposes, it can be very frustrating for the pathologist to find that there is apparently little correlation between any visible morphological abnormalities and the documented clinical disease. There may be little or nothing detectable in the spleen histologically which can be regarded as abnormal, or there may be obvious abnormalities which cannot be attributed with confidence to a specific cause.

Why is splenic pathology perceived to be difficult?

Pathological changes which would cause no diagnostic problem in another tissue may seem less straightforward when encountered in the spleen. There are a variety of reasons for this, some genuinely related to a current relative lack of understanding of normal physiological processes within splenic components and their corresponding morphology. However, a major problem is often the poor quality of histological material obtained from splenectomies, compounded by inadequate supporting clinical information.

Whatever their size, whether suspected to be pathological or not, spleens usually arrive in histopathology departments having spent several hours immersed in fixative but otherwise untouched. The result is immediately apparent when the first cut is made through the organ: a rind of tissue 0.5 cm thick beneath the capsule is fixed, while all deeper tissue is red and already partly autolysed due to inadequate penetration of fixative (Fig. 1.1). Whatever is done subsequently by way of slicing and further fixation (Figs. 1.2 and 1.3), the damage has been done and the resulting histological sections will show good tissue preservation only in the immediate subcapsular area.

There is no doubt that spleen is difficult

tissue in which to achieve good fixation, since its high content of red blood cells is inhibitory to adequate penetration of fixative solutions. However, much of this problem can be avoided by prompt delivery of the unfixed organ to the histopathology laboratory so that primary fixation can be achieved after careful slicing of the tissue.

A second important problem is that spleens sent for histopathological analysis are often accompanied by minimal, or no, clinical details, particularly in cases where removal has been considered by the surgeon to be incidental to the major surgical purpose (nephrectomy, gastrectomy, abdominal aneurysm repair, etc.). Surgeons performing splenectomy for diagnostic purposes are often acting on behalf of other clinicians and may have no detailed knowledge of the patient's underlying disease. When the spleen has been traumatized, there may be no indication of whether minor intra-operative trauma or a major road traffic accident was the cause. In cases of splenic trauma due to major abdominal injury, the time interval between injury and surgery is rarely stated. These pieces of information are of fundamental importance. An injury to the spleen, like a wound in any other tissue, may vary from insignificant to extensive and will undergo sequential reparative changes during the days following injury.

Thirdly, many pathologists lack a clear understanding of normal splenic anatomy and physiology. We rarely see genuinely normal spleens as surgical specimens, and rapid post-mortem autolysis results in generally poor morphological preservation of the spleen at autopsy.

Normal spleens from experimental animals and spleens obtained at defined time-points following immunological challenge or injury in such animals offer insight into splenic pathophysiology. However, the anatomy and functions of the spleen differ considerably between species, and data

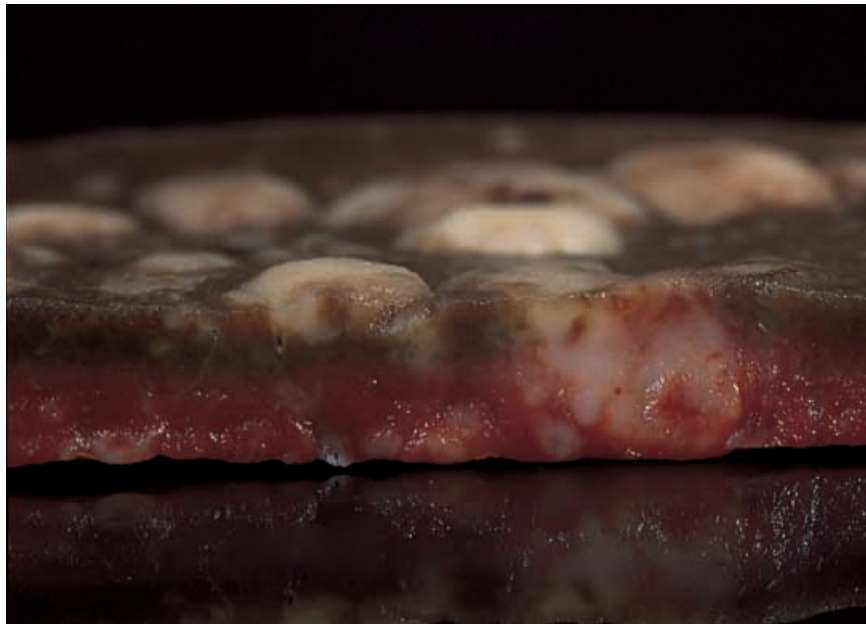

Fig. 1.3. Slice of tissue prepared from a spleen which had been received fresh and sliced at 1 cm intervals prior to immersion in formalin. Twenty-four hours later, each portion of spleen was re-sliced at 5 mm thickness. A cross-section through one such piece is shown. This photograph emphasizes the slow penetration of formalin into splenic tissue, even after appropriate initial handling of the organ.

from experimental animals cannot be assumed to reflect accurately processes occurring in humans. For instance, the spleen in rodents is a major haemopoietic organ throughout life, while there is little evidence to support such a function for the normal fetal or adult human spleen. Rodent spleens also differ significantly in structure from those of humans, particularly in the organization of white pulp marginal zones and the perifollicular vasculature. The spleens of cats and dogs have an important physiological role as a reservoir for blood cells. They have considerable amounts of capsular and trabecular smooth muscle to assist this function, and normal spleen volume may vary widely in these species. Similar reservoir activity in the human spleen is usually evidence of underlying pathology causing undesirable sequestration of blood elements as, for example, in hereditary spherocytosis.

What does the surgeon or physician want from the pathologist?

For incidental splenectomies, the surgeon requires answers to two main questions. First, is there involvement of the spleen (and/or splenic hilar lymph nodes) by primary pathology directly related to the cause of surgery? For example, the presence or absence of metastasis or direct spread from a gastric or colonic carcinoma should, obviously, be reported. Secondly, is there any significant coincidental pathology present or can any variations from normal appearances be explained by the spleen's proximity to the primary site of disease? It is this second question which can be particularly difficult to answer with confidence.

For therapeutic splenectomies, confirmation of the diagnosis and exclusion of additional pathology are the major requirements from pathological examination. It is also important to comment

specifically upon the presence of capsular damage or other features suggestive that spillage of splenic tissue could have occurred during surgery. Such spillage may lead to splenosis and subsequent return of the disease or symptoms for which splenectomy was performed.

In the case of splenectomy undertaken for diagnostic purposes, elucidation of the primary abnormality (e.g. the cause of unexplained splenomegaly) is clearly required but any additional pathology and/or evidence of injury should also be recorded, for the reasons outlined above.

What information does the pathologist require?

Patient identification data, including date of birth or age, are essential. Age is particularly important as splenic function, and consequently morphology, varies throughout life. The purpose of splenectomy should be stated clearly. If it is incidental, details of the primary diagnosis and surgical procedure are required. If there has been abdominal trauma, its nature and timing are important, for the reasons described earlier.

Where there is known or suspected primary pathology, its nature should be stated, as a guide to organizing ancillary investigations (see below) as well as to assist in morphological assessment. Details of any concurrent diseases should also be known. For conditions such as AIHA and ITP, it is important to know whether the patient has been receiving corticosteroid therapy, and at what dosage, prior to surgery. Prolonged administration of corticosteroids for these, and other, disorders may have profoundly suppressive effects on splenic white pulp, as on lymphoid tissue elsewhere in the body.

Since the introduction of vaccines to protect against pneumococcal and *Haemophilus influenzae* type B infections, it is also desirable to know whether these have

been administered and when. The spleen is a major site for the production of immune responses to such encapsulated organisms, and non-vaccinated subjects are at significant risk of infection by these agents following splenectomy. Consequently, with the exception of emergency and unanticipated cases, most patients undergoing splenectomy will have been pre-vaccinated. Specific morphological changes in the spleen secondary to vaccination have not been described in the published literature. Only by careful recording of vaccination details will it be possible, over time, to acquire experience of vaccinated versus non-vaccinated appearances in otherwise equivalent splenectomy specimens and determine the extent of any changes which can confidently be ascribed to vaccination per se.

How can fixation and processing be optimized to give the best possible histology?

Ideally, all spleens should be transported directly to the histopathology laboratory as soon as possible after removal from the patient. They should be sent unfixed in a dry container, accompanied by informative clinical details as described above.

On receipt in the laboratory, the spleen should be weighed, minus any associated blood clot but otherwise undisturbed, since slicing may cause significant loss of blood (and hence weight) from a congested spleen. Very large spleens may be weighed in their containers using bathroom scales. The weight of an equivalent empty container is subtracted to obtain the actual weight of the spleen. Measurements of splenic vertical length, medio-lateral width and antero-posterior depth are desirable, but normal values for these parameters are highly variable. The state of the capsule (intact or disrupted) should be noted,

together with any abnormal appearances such as sugar-icing or subcapsular haematoma. The presence or absence of hilar lymph nodes (plus their number and size, if present) and any hilar vascular abnormalities should be described.

The spleen should then be sliced at 0.5–1.0 cm intervals (Fig. 1.4) and the parenchyma described. Particular features to note are congestion, prominence of white pulp nodules, haemorrhagic foci, infarctions, cysts and any obvious tumour masses. The value of macroscopic assessment in splenectomy specimens has been inadequately emphasized in the past. Much useful information can be gained from careful examination of the sliced tissue before and after fixation, as we shall demonstrate in subsequent chapters.

Following examination, the slices should be rinsed by gentle agitation in a large volume of 10% neutral-buffered formalin (or other fixative, according to local practice), to remove excessive blood. They should then be submerged, preferably flat and interleaved with absorbent paper, in clean fixative solution for 24 hours. It is important to use a generously sized container and abundant fixative solution so that the fluid can penetrate freely between individual slices which are not packed tightly together. After 24 hours, although fixation will be incomplete, tissue blocks of 2–3 mm in thickness should be prepared from selected slices and put to fix in cassettes (to avoid distortion of the tissue pieces) for a further 24 hours. In our experience, this procedure yields histological sections of better quality than those obtained by blocking tissue straight from fresh slices of spleen. Also, slicing spleen thinly for insertion into cassettes is much easier after partial fixation has made the tissue somewhat more rigid than it is in its fresh state.

If it is unavoidable that a spleen is sent to the laboratory in fixative, it should be measured, described, sliced and fixed further as



Fig. 1.4. Partly sliced spleen demonstrating the preparation of complete horizontal cross-sections through the organ at 0.5 to 1 cm intervals.

outlined above, as soon as possible. Fixation will be best in the subcapsular tissue and blocks should be taken from here, unless this is not representative (e.g. in the case of a focal lesion deep within the organ). Tissue from the centre of the spleen, even after further fixation, will yield suboptimal histology. Any hilar lymph nodes present should be described and sampled.

We recommend that several tissue blocks should be taken for histological examination, even in the case of an incidental splenectomy. A useful guide is to sample the superior and inferior borders, the hilum and the lateral convex border of the spleen as a minimum. In this way, individual pathologists can easily accumulate reference material upon which to base their appreciation of normal and abnormal splenic morphology. We perform Giemsa, reticulin, Perls' and periodic acid-Schiff's stains on one block in addition to routine H&E staining.

Ancillary investigations

Well-fixed splenic tissue can be stained successfully using the tinctorial methods mentioned above. In addition, immunohistochemistry can be performed as for other formalin-fixed, paraffin-embedded tissues, with no special modifications. Where antigen retrieval methods such as proteolysis or wet heat techniques (microwave oven or pressure cooker heating in appropriate buffered solutions) are required, slightly longer exposure times may be needed, reflecting the relatively prolonged fixation to which spleens are usually subjected.

When the spleen has been received fresh, small pieces can be removed under sterile conditions to disperse cells into suitable media for immunostaining, biochemical, cytogenetic and molecular genetic analysis. It may also be useful to make imprints from

small pieces of tissue for rapid cytological assessment. Imprinting is made easier by drying the tissue very gently on a piece of fibre-free filter paper before touching it onto the glass slide(s). This removes some of the blood from the tissue surface and permits better assessment of nucleated cells of interest, uncontaminated by red blood cells.

Such investigations may be appropriate at present in cases of suspected lymphoma, myeloproliferative or histiocyte storage disorders. As understanding of the cellular mechanisms underlying these and other diseases will undoubtedly continue to improve, requirement for such techniques to be performed on splenectomy specimens is likely to expand.

Splenic biopsy, fine needle aspiration and laparoscopic splenectomy

Historically, there has been a reluctance to perform needle biopsies for histological or cytological analysis of the spleen, because of the significant risk of haemorrhage following puncture of the spleen's delicate capsule. With improved imaging techniques to guide the insertion of biopsy needles, however, sampling of solid lesions within the spleen has been practised increasingly in recent years. There is a need for pathologists to understand the potential uses and pitfalls of splenic needle biopsy samples. As with all aspects of splenic pathology, a key factor is awareness of the variety of normal appearances which may be present in such small samples, ranging from trabecular connective tissue components to normal lymphoid structures and different subcompartments of red pulp.

To complicate matters further for the histopathologist, techniques for laparoscopic splenectomy are becoming established in the surgical repertoire (Delaitre & Pitre, 1997; Trias et al., 1998). With such methods, splenic tissue may be removed piecemeal or

by aspiration via laparoscopic instruments. This has profound implications for the nature of any splenic tissue which may be submitted subsequently for histological analysis. To date, laparoscopic splenectomy has been used mainly in cases where diagnosis is not primarily at issue and where it is considered desirable to preserve some splenic function, e.g. in hereditary spherocytosis and ITP in young patients (Watson et al., 1997). However, there can be issues of differential diagnosis even in some of these patients (such as the possibility of HIV-associated thrombocytopenia mimicking ITP). It remains to be determined, as pathological experience of tissue from such procedures increases, whether it will pose major new diagnostic challenges in an already difficult field. Laparoscopic and open partial splenectomy techniques are also in development (Petroianu et al., 1997).

Implications of splenectomy for the patient

Splenectomy is not without hazard. Apart from technical risks specifically associated with the surgical procedures employed to remove the spleen, lack of splenic function post-splenectomy leaves patients at increased risk of infection, particularly by encapsulated bacteria. The risk is greatest in children and young adults but is not insignificant in older individuals (see Meekes et al., 1996; Working Party of the British Committee for Standards in Haematology Clinical Haematology Task Force, 1996). It is not yet known whether vaccination against pneumococci, meningococci and *Haemophilus influenzae* will have a major impact on the occurrence of post-splenectomy infections.

It is unclear whether useful splenic function is lost by the removal of a spleen massively replaced by lymphoid or haemopoietic malignancy and it is also not known

whether valuable haemopoiesis is lost in the latter situation. Functional studies to attempt to define splenic haemopoietic function in such patients are, as yet, imperfect.

Summary

Provided with high-quality histological material and good clinical background information it is possible to make a rational assessment of spleen structure and any pathological changes present. In the following chapters, it is our aim to provide a systematic overview of splenic pathology in the context of its relationship to normal structure, functions and appearances of the organ.

REFERENCES

- Delaitre, B. & Pitre, J. (1997). Laparoscopic splenectomy versus open splenectomy: a comparative study. *Hepatology and Gastroenterology*, **44**, 45–9.
- Meekes, I., Van der Staak, F & Van Oostrom, C. (1996). Results of splenectomy performed on a group of 91 children. *European Journal of Pediatric Surgery*, **6**, 19–22.
- Petroianu, A., da Silva, R.G., Simal, C.J., de Carvalho, D.G. & da Silva, R.A. (1997). Late post-operative follow-up of patients subjected to subtotal splenectomy. *American Surgeon*, **63**, 735–40.
- Trias, M., Targaroni, E.M., Espert, J.J. & Balague, C. (1998). Laparoscopic surgery for splenic disorders. Lessons learned from a series of 64 cases. *Surgical Endoscopy*, **12**, 66–72.
- Watson, D.I., Coventry, B.J., Chin, T., Gill, P.G. & Malycha, P. (1997). Laparoscopic versus open splenectomy for immune thrombocytopenic purpura. *Surgery*, **121**, 18–22.
- Working Party of the British Committee for Standards in Haematology Clinical Haematology Task Force (1996). Guidelines for the prevention and treatment of infection in patients with an absent or dysfunctional spleen. *British Medical Journal*, **312**, 430–4.