

INTRODUCTION

Getting the best scan

Choosing a probe

Select the most appropriate probe for the particular scan required. Probes vary in their:

- operating frequency range – higher ultrasound frequencies provide better discrimination of fine detail but have lower penetration because of increased attenuation by the tissues.
- physical size – the smaller the probe, the smaller its ‘footprint’ when placed on the patient.
- the width of the tissue field scanned – an ultrasound probe scans a ‘slice’ of tissue approximately 1–3 mm thick, with a width dependent on the size of the probe.

Common types of probe available (Fig. 1) are:

Linear These probes have a flat face and give a parallel-sided scan field approximately 1 mm ‘thick’. Linear probes operate at frequencies typically between 5 and 18 MHz. They come in different widths, between 20 and 40 mm, with correspondingly different lengths of probe footprint. These are the best general-purpose probes.

Hockey-stick These are small probes that can be held with a ‘fountain-pen’ grip. They are appropriate for small or paediatric patients. They are also useful for awkward areas such as close to the clavicle or posterior to the medial malleolus, where the physical size of the wider probes may make it difficult to manipulate the probe or obtain good skin contact. The less the width of the probe, the smaller its footprint, but the narrower the field covered in the scan and the more difficult it is to identify the anatomy in the scan.

Curvilinear These probes have a curved face giving a fan-shaped scan field. The field is diverging, with

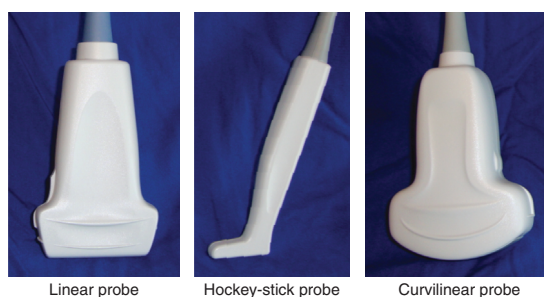


Fig 1 Three common types of ultrasound probe

curvilinear distortion in the horizontal direction – analogous to that seen with a fish-eye lens in photography. A more panoramic view is therefore obtained in the scan, which can make identification of the local anatomy easier. Curvilinear probes generally operate at relatively lower frequencies (typically 2–5 MHz), giving greater depths of penetration but with coarser discrimination.

Choosing the frequency

The frequency of ultrasound can significantly alter the appearance of the scan obtained. The frequency will determine both the depth of penetration and the discrimination of detail in the scan. Unfortunately there is a trade-off between depth of penetration and discrimination of detail. The higher the frequency the better the resolution of detail in the scan, but the lower the penetration of tissues. Typically a linear probe operating at 10 MHz gives good resolution of detail but only provides good penetration to depths of 2–3 cm. Targets beyond this range are more difficult to visualize (Fig. 2).

A curvilinear probe working at 2–5 MHz can penetrate soft tissues reasonably well up to 4–10 cm, but the discrimination of detail is coarser (Fig. 3).

INTRODUCTION

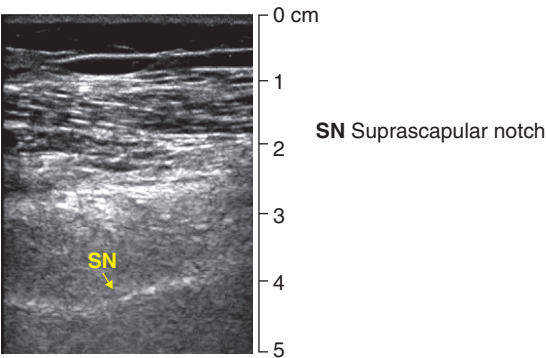


Fig 2 High resolution but low penetration: a high-resolution scan of the suprascapular notch, using a linear probe at 10 MHz

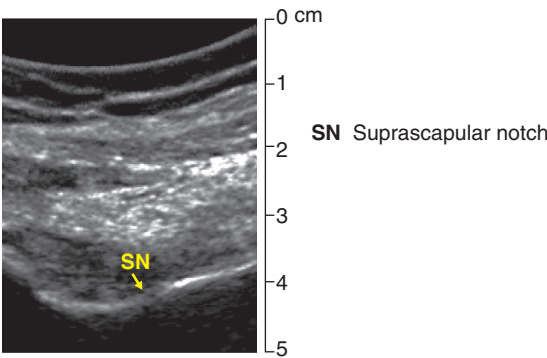


Fig 3 High penetration but low resolution: a low-resolution scan of the suprascapular notch, using a curvilinear probe at 4 MHz

Gain control

This control is equivalent to the ‘brightness’ control, and it may make targets easier to see in the scan (Fig. 4). It changes the overall appearance of the scan from dark (black) to bright (white). It will not necessarily make targets easier to distinguish or identify. More sophisticated machines can increase the gain at a selected depth, known as time gain compensation (TGC). This feature can be useful when trying to visualize more distal targets at depths where the penetration of the ultrasound is poor.

Depth

Use the depth control to place the target area at approximately two-thirds of the total depth of the scan.

Focus

Some machines have a focus control which enhances image quality at a chosen level. This should be set just deep to the target area.

Identifying the anatomy in a scan

Gross anatomy

Orientation in an ultrasound scan is predominantly a process of pattern recognition. Knowledge of the anatomy in the region being scanned is essential in interpreting and identifying structures in the scan. Using the surface anatomy to aid accurate and consistent placement of the probe helps to obtain a scan with a familiar pattern.

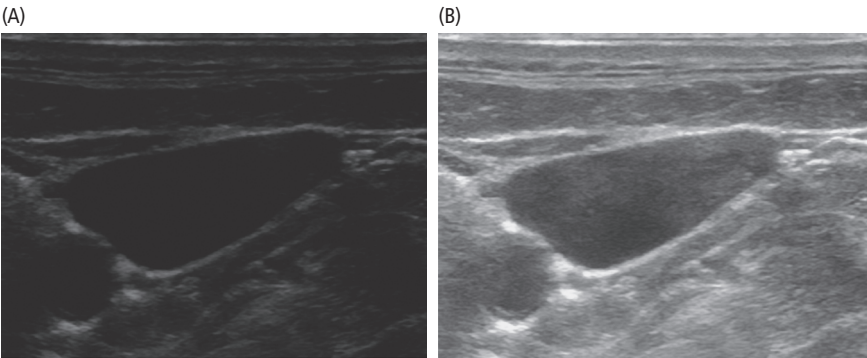


Fig 4 A scan of the carotid artery and internal jugular vein: (A) with the gain adjusted too low; (B) with the scan gain increased

INTRODUCTION

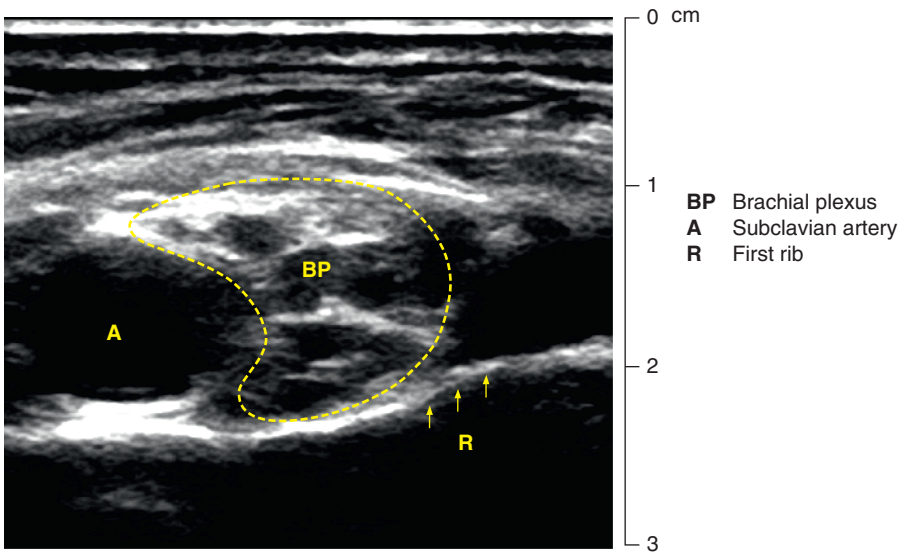


Fig 5 Vascular and bony landmarks in an ultrasound scan: locating the brachial plexus

Scan landmarks

Use vascular and bony landmarks to orientate in a scan. For example, use the subclavian artery and first rib to orientate in a supraclavicular scan of the brachial plexus (Fig. 5).

Tracking

In some patients it may prove difficult to identify a target structure in a scan with the probe at a particular location. This can often be solved by identifying the structure at an alternative location where it is easy to see, and then ‘tracking’ it back to the desired location.

For example, if it is proving difficult to find the ulnar nerve at mid forearm level, first find the nerve at the wrist, where it can easily be located between the ulnar artery and the flexor carpi ulnaris tendon. Then ‘track’ it proximally to forearm level by slowly sliding the probe up the forearm while taking care to keep the ulnar nerve in view (Fig. 6). As the nerve and artery are tracked proximally it can be seen that although the nerve starts adjacent to the artery in the wrist its course diverges from the artery in the proximal forearm, where it can be blocked with reduced risk of arterial puncture.

Anisotropy

Slight adjustments of the probe about its long axis (tilting the probe) when at the scan position can greatly improve the view of a target or even reveal its presence when previously unseen (Fig. 7). This is a result of altering the angle at which the ultrasound waves strike the target and thus optimizing the reflections received by the probe. This effect is referred to as *anisotropy*.

Fig. 8 compares two views of the median nerve obtained with the probe in exactly the same position on the forearm. The only difference between the two scans is a slight change of the probe angle about its long axis, to maximize and minimize the anisotropic effect.

Recognizing different tissues in an ultrasound scan

The use of ultrasound when scanning body tissues demonstrates some differences between tissues. Detail in the scans is dependent on the wavelength, which is inversely dependent on frequency. The production of targets (bright reflections) in a scan relies on reflection of ultrasound, the reflected waves having to pass back to the probe in order to be

INTRODUCTION

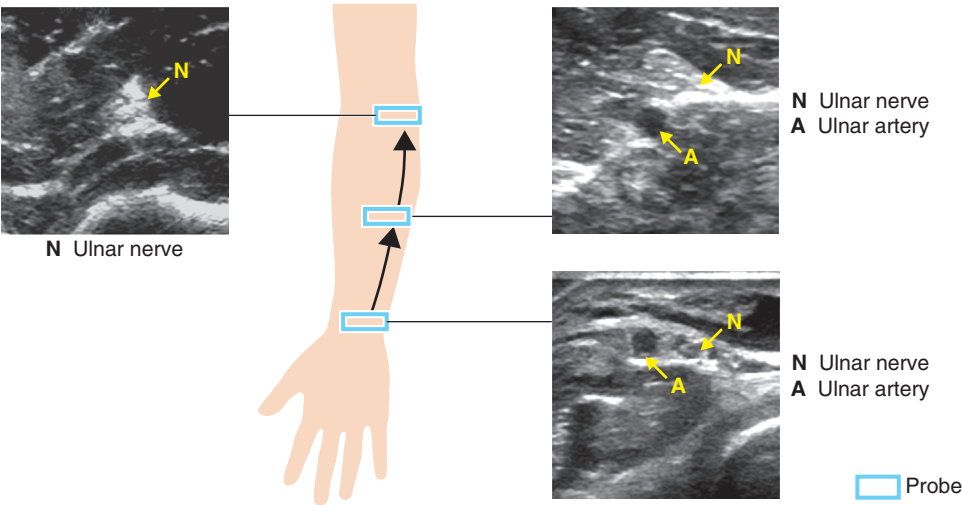


Fig 6 Tracking the ulnar nerve from wrist to forearm

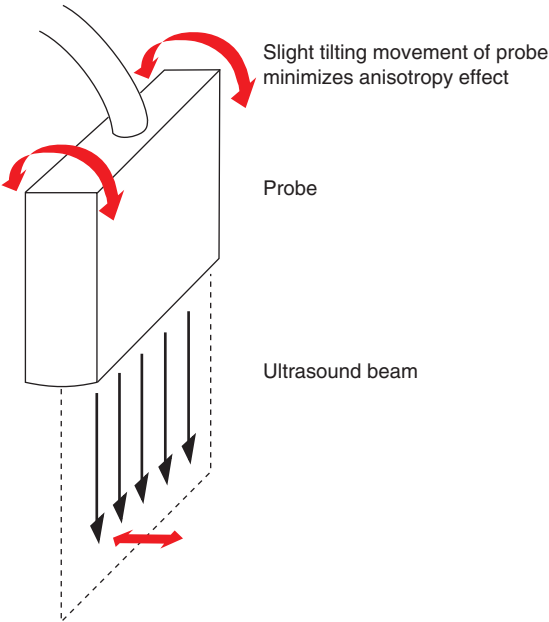


Fig 7 Tilting the probe to minimize anisotropy

received. This means that the visibility of a target relies on reflection and can be attenuated by scattering. Reflection at a boundary between different tissues is determined by the differences in acoustic impedances of the tissues.

The best-defined targets have boundaries (surfaces) which separate media with the greatest mismatch of acoustic impedances – for example, between soft tissue and air, soft tissue and bone, soft tissue and fluid. Some representative acoustic impedances are shown in Table 1.

Modern machines have tissue harmonic imaging, which uses harmonics of the ultrasound beam to reduce the effects of scattering and improve tissue resolution.

Nerves

Peripheral nerves have a granular appearance in cross-section due to the echogenicity of the endoneurium tissue around the nerve fascicles (Fig. 9). They appear less echogenic when viewed more centrally. In longitudinal section the fascicles are visible as parallel streaks within the nerve.

Tendons

Tendons may easily be confused with nerves, but usually the granularity in cross-section and the streaking in longitudinal section are finer, and the appearance is more homogeneous (Fig. 10). Distinguish between nerves and tendons in a scan by tracking. Track nerves from areas where they are

INTRODUCTION

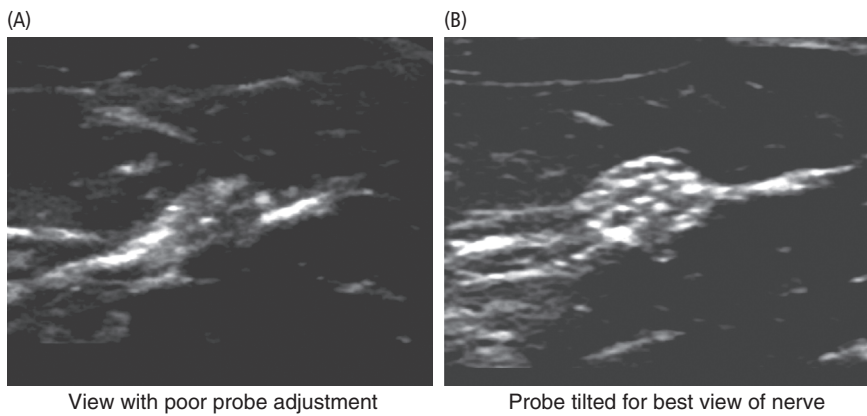


Fig 8 Two views of the median nerve: (A) poor and (B) good probe adjustment to reduce anisotropy effect

more easily identifiable, or track tendons to the muscles they are attached to. Alternatively, ask the patient to make appropriate movements, which cause the tendons to move in the scan while the nerves remain relatively stationary.

Muscle

Muscle is coarsely speckled in cross-section, with more dense connective tissue outlining the fascicles.

Table 1 Values of acoustic impedance for different tissues

Tissue	Velocity of sound (m s ⁻¹)	Acoustic impedance (kg m ⁻² s ⁻¹) × 10 ⁻⁶
Gas	330	0.0004
Fat	1470	1.43
Blood	1570	1.53
Muscle	1568	1.63
Bone	4080	6.12

In longitudinal section the fascicles produce coarse irregular striations (Fig. 11).

Bone

Bone can only be visualized in a scan by the proximal surface that is exposed to the incident ultrasound. Since the ultrasound waves do not penetrate this proximal boundary (as they do in the case of soft tissue structures such as blood vessels and nerves), the proximal surface of a bone in the scan leaves a dark region or ‘drop-out shadow’ distally.

Therefore bones do not appear in an ultrasound scan as a two-dimensional structure or cross-section. Instead, bones are recognized as hyperechoic (bright) profiles proximal to a dark drop-out shadow (Fig. 12).

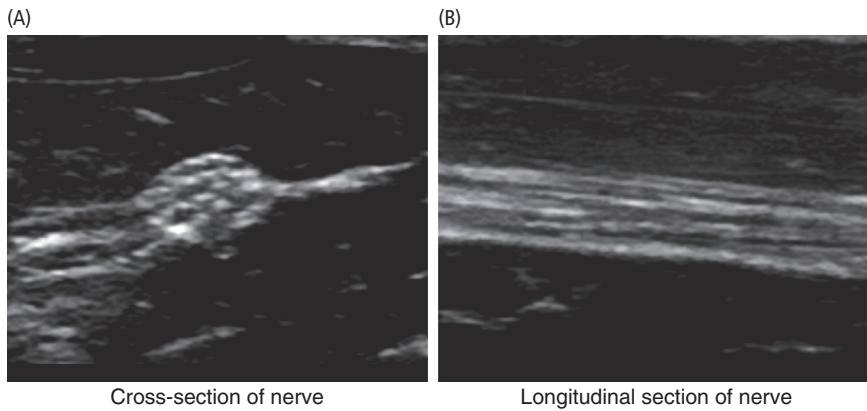


Fig 9 Ultrasound appearance of nerve – fascicular pattern

INTRODUCTION

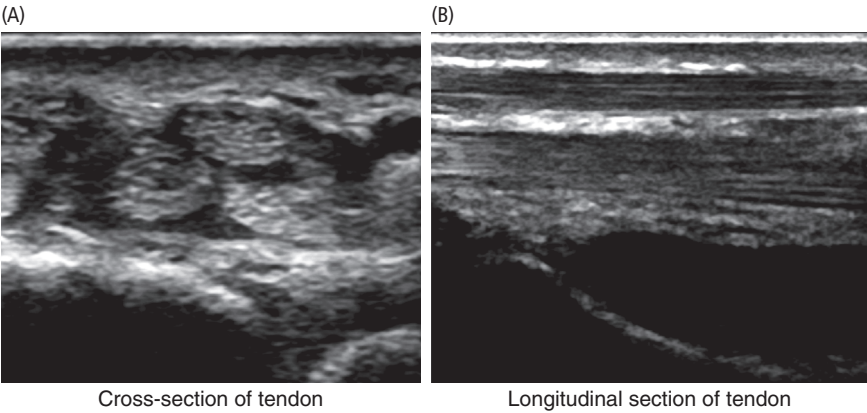


Fig 10 Ultrasound appearance of tendon – fibrillar pattern

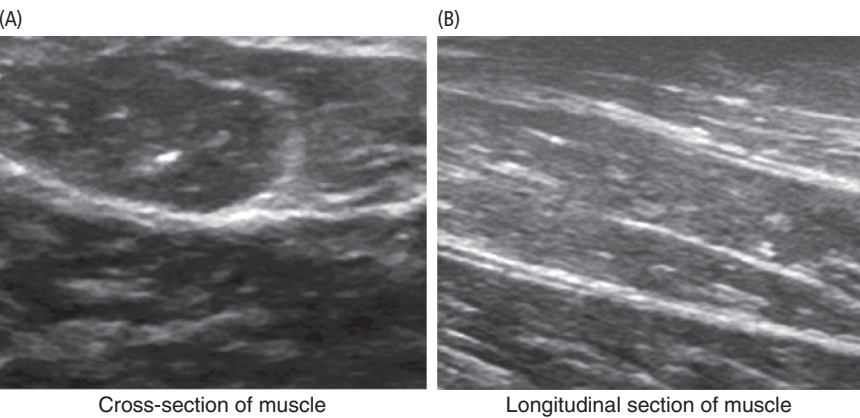


Fig 11 Ultrasound appearance of muscle

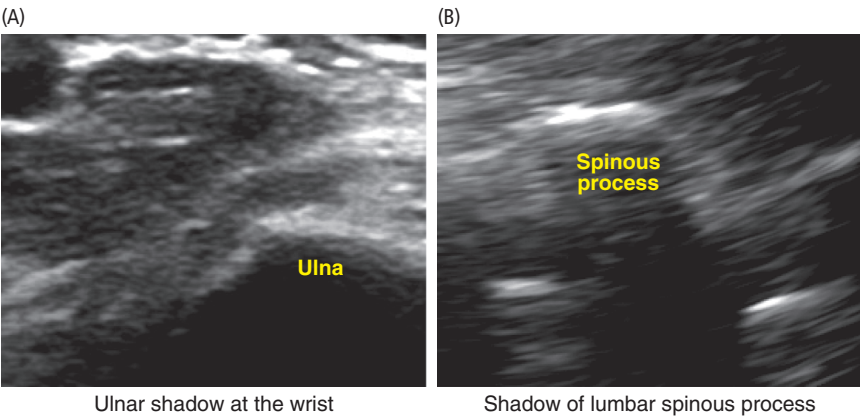


Fig 12 Bone profiles and drop-out shadows in an ultrasound scan

Blood vessels

Arteries and veins are readily recognized because of the low echogenicity of the blood they contain. Arteries retain their circular cross-section and pulsate even when pressure is applied to the probe,

unlike accompanying veins, which are of greater cross-sectional area but with a more irregular cross-section and a tendency to collapse when pressure is applied to the probe (Fig. 13). Occasionally a valve may be seen in the lumen of a large central vein as a pulsatile intraluminal echo.

INTRODUCTION

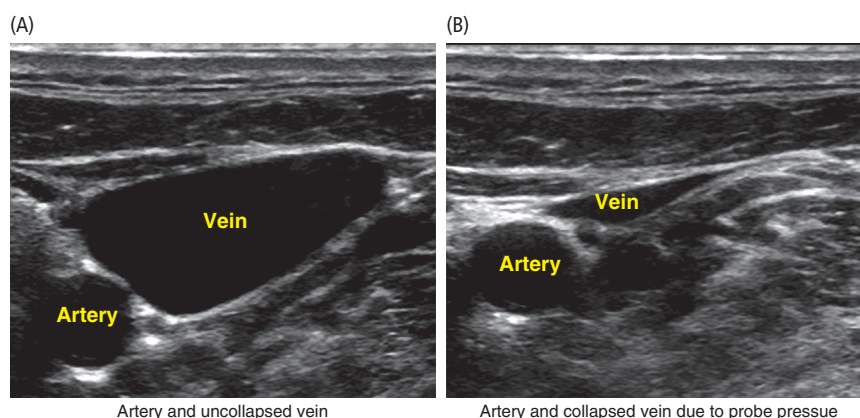


Fig 13 Scans of an artery and a vein, showing collapse of vein with pressure applied to probe

Post-cystic enhancement

Often a bright area can be seen distal to a fluid-filled cyst or vessel (Fig. 14). This is the combined result of (1) low attenuation of ultrasound waves as they pass through the vessel, (2) refraction and (3) 'edge shadows'. The edge shadows are caused by scattering of the incident ultrasound waves from the edges of the vessel.

Uses of ultrasound in procedures

Guiding the needle in regional anaesthesia

Use of ultrasound enables real-time guidance of the needle in regional anaesthesia. The ultrasound beam is only approximately 1 mm in thickness. In order to guide the needle it is necessary to obtain the best possible view of the needle and needle tip.

Obtaining a good view of the needle

A good view of the needle in the scan requires the needle to be in the plane of the ultrasound beam. In addition, the angle between the needle and the face of the probe should be as small as possible in order to maximize the reflection of ultrasound waves back to the probe (Fig. 15). When the angle between the needle and probe face is greater than 45 degrees poor visibility of the needle results, since the ultrasound is reflected from the needle at an angle rather than back to the probe (high-visibility needles can improve this poor visibility).

Ideally, try to maintain an angle of less than 30 degrees between needle and probe face. The best view of the needle is obtained when the needle is parallel to the face of the probe. Keeping the bevel of the needle tip facing the probe improves needle tip visualization.

In-plane and out-of-plane needling techniques

In-plane needling refers to needle insertion parallel to the ultrasound beam, keeping the needle within the plane of the beam, so that the length of the needle and its tip are visualized during insertion. Out-of-plane needle insertion is performed with the needle perpendicular to the ultrasound beam. In this case the needle is only visualized as a hyperechoic spot where it crosses the plane of the ultrasound beam.

In-plane needling As long as the whole needle, and in particular its tip, lies in the plane of the ultrasound beam, it can be observed as it passes along its track, and puncturing unwanted structures such as blood vessels and pleura can be avoided (Fig. 16A). However, because the ultrasound beam is only 1–3 mm thick, it is easy to only obtain a partial view of the needle, leaving the tip invisible because it is out of the plane of the ultrasound beam (Fig. 16B). In such a case the puncture of unwanted structures is more likely. Therefore in-plane needling is the safest technique to use, provided good alignment of the needle is maintained.

INTRODUCTION

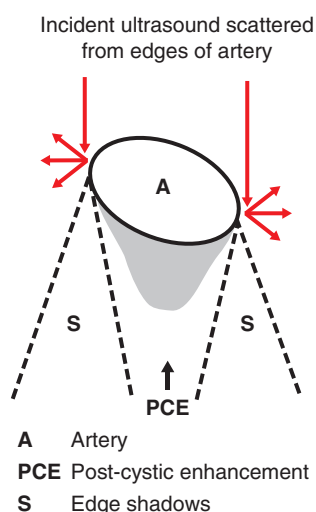
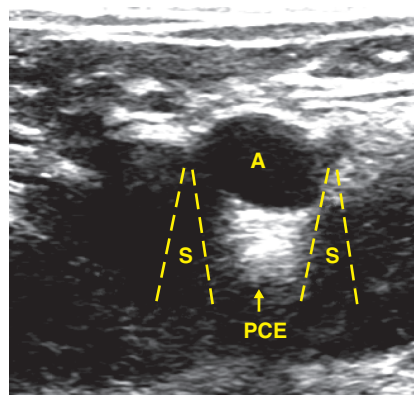


Fig 14 Post-cystic enhancement

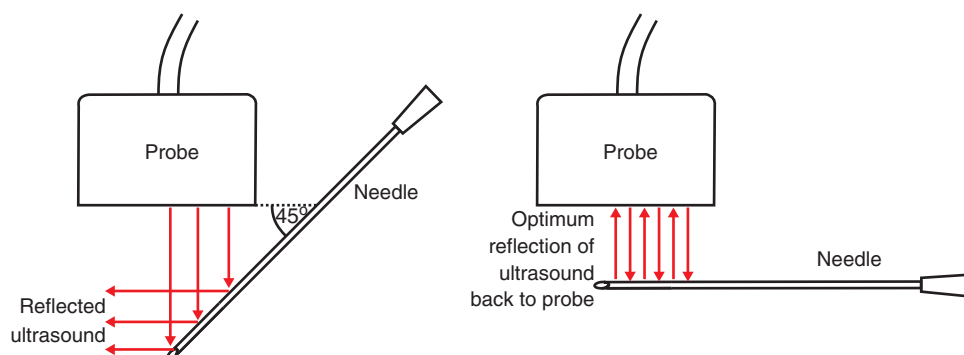


Fig 15 The effect of different angles between needle and probe: poor visibility with a steep angle; good visibility when the needle is parallel to the probe

Out-of-plane needling Often gives an advantage in identifying surrounding anatomy but does increase the risks of puncturing unwanted structures, since the needle tip is out of plane and not visible. A hyperechoic 'dot' in the scan marks the point at which the needle crosses the plane of the ultrasound beam. The position of the needle tip can be located by sliding the probe along the needle axis until this hyperechoic dot disappears. In this position, tilting the probe about its long axis causes the needle tip to appear and disappear, confirming its position in the ultrasound beam. Out-of-plane needling may be used for practical reasons such as passing a catheter for

continuous infusion blockade. In such a case the catheter needs to be inserted parallel to a nerve, and needling out of plane can make this significantly easier (Fig. 17). The track of the needle in out-of-plane needling is observed indirectly on an ultrasound scan by looking for the movement of tissue in the scan caused by the passage of the needle.

Observation of local anaesthetic spread

When performing regional anaesthetic blocks, the distribution or spread of the injected local anaesthetic can determine whether or not an

INTRODUCTION

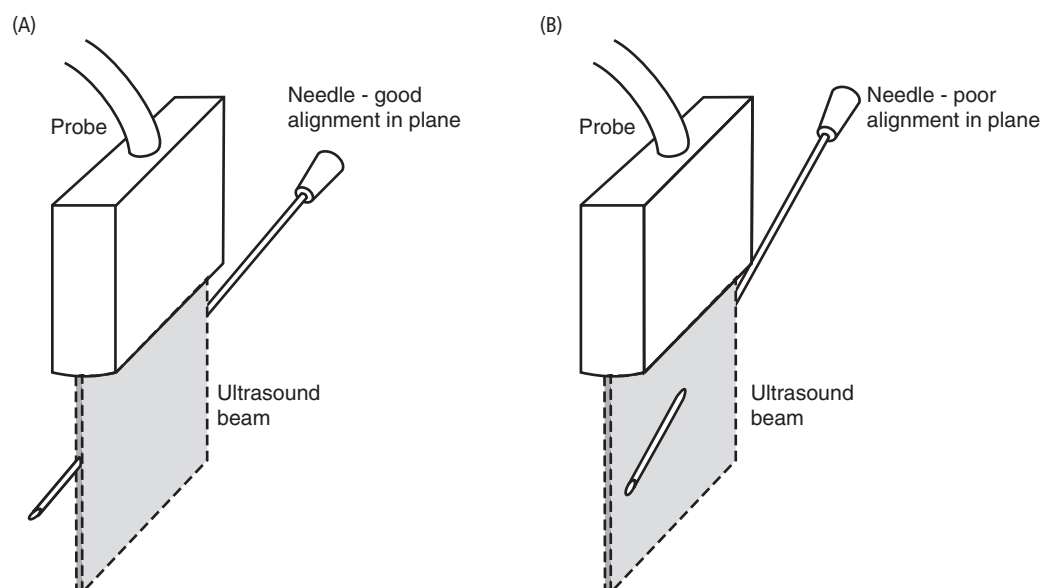


Fig 16 In-plane needling with (A) good and (B) poor alignment (needle tip out of plane)

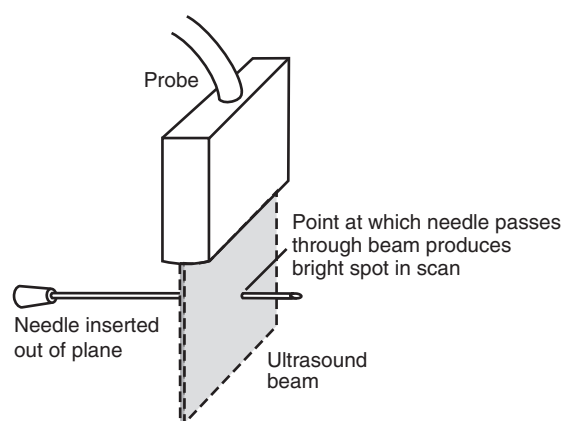


Fig 17 Out-of-plane needling

effective block is obtained. Thus when using ultrasound guidance for regional anaesthesia it is useful to observe the spread of local anaesthetic as it is injected.

Fig. 18 shows how the local anaesthetic in a femoral nerve block can spread away from the nerve (B) rather than around the nerve (A). This might occur even in the presence of good muscle twitches if a nerve stimulator is used.

Good spread of local anaesthetic in a regional block can be observed in real time as the local anaesthetic, which is echolucent, can be seen to surround the target nerves as injection takes place.

Fig. 19 shows an ultrasound scan of the supraclavicular brachial plexus, with local anaesthetic surrounding the trunks of the plexus.

Checking perineural catheter placement

Insertion of a perineural catheter can be used in cases where continuous infusion blockade is required (Fig. 20). Insertion of a catheter to lie alongside the nerve being blocked can sometimes be difficult, as the track of the catheter may not stay close to the nerve. Needling out of plane can facilitate passing the catheter. The final catheter position can be checked using ultrasound, but the catheter usually appears only intermittently as bright dots in the scan. Injection of a small quantity of air under ultrasound observation can also help confirm placement.

INTRODUCTION

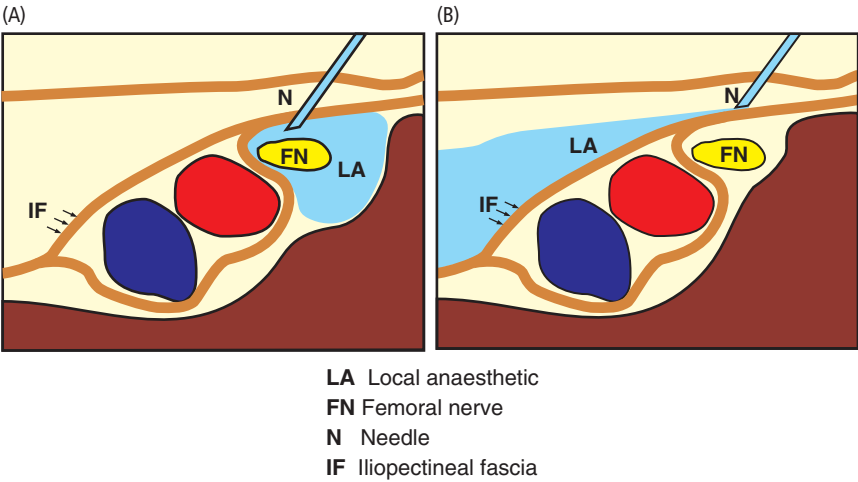


Fig 18 (A) Good spread and (B) poor spread of local anaesthetic in a femoral nerve block, depending on whether the needle penetrates the iliopectineal fascia

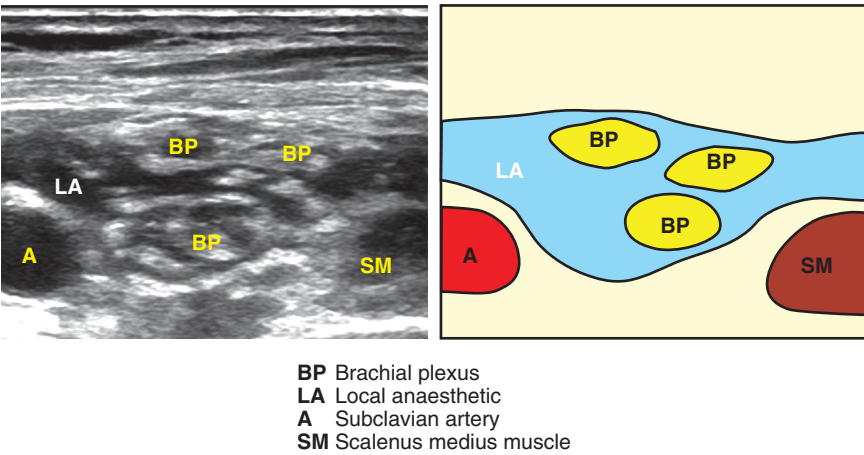


Fig 19 Spread of local anaesthetic in brachial plexus block, showing local anaesthetic surrounding the divisions of the plexus

Guiding intravascular cannulation

Intravascular cannulation can be guided by ultrasound, either for central venous cannulation or for peripheral vessel cannulation in cases where peripheral vessels are not easily visualized.

Ultrasound can be used to detect an appropriate vessel, check entry of a guide wire into the vessel and check final placement of the cannula into the vessel. Fig. 21 shows the stages in cannulation of an internal jugular vein, using an in-plane technique.