



## Introduction

Anna L. Waterbrook

Musculoskeletal training is generally under-represented in medical training and residency curriculums. There is a general deficit in musculoskeletal knowledge amongst current medical students, residents and practicing medical providers despite the fact that musculoskeletal complaints are among the most common complaints seen in the emergency department (ED). Currently, most educational resources on this subject are geared towards orthopedists and nonoperative sports medicine physicians however they are often too detailed for the average practicing emergency medicine (EM) provider. EM providers need a few, high-yield musculoskeletal physical exam skills to help them diagnose and rule out life-threatening conditions, while also recognizing common conditions.

This is a handbook written by trained sports EM physicians for EM providers as a guide to high-yield physical exam skills and management of sports injuries appropriate for the EM provider practicing in the ED. This book may also be useful for the sports-fellowship-bound EM resident, or the EM provider with a special interest in sports

medicine. Each chapter is dedicated to a specific joint or joints and includes the basics of a high-yield musculoskeletal physical examination, including inspection, palpation, range of motion, special tests, as well as neurovascular and skin exam. Corresponding figures of essential anatomy, pictures of physical exam maneuvers, and clinical correlations are included. Emergent and common musculoskeletal conditions for each joint are discussed, as is the appropriate ED management for each condition. Additional chapter topics include sports-related concussions, sports cardiology, heat illness, and common splints used in the ED.

This book is not meant to be a comprehensive sports medicine book. Thus, each chapter does not include every possible diagnosis or physical exam skill for each joint, but rather focuses on the emergent and common conditions seen in the ED. While every effort has been made to ensure the accuracy of the information presented, neither the author nor the publishing company assumes any responsibility for injury to persons or property.

## Chapter

## 1

# Shoulder

Christopher Guyer

## Background/Epidemiology

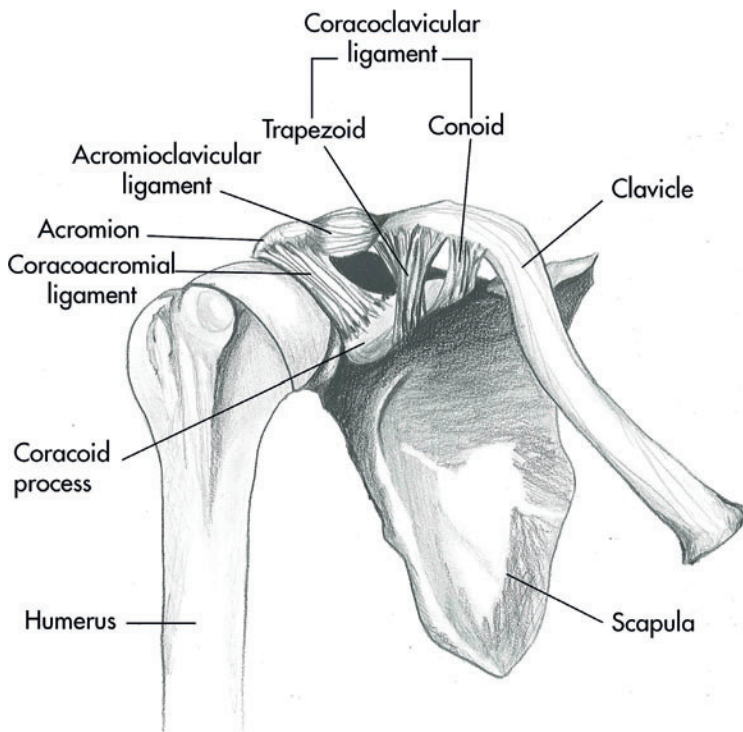
- Shoulder pain is a common chief complaint in the emergency department (ED). Prevalence estimates of shoulder pain vary widely across different populations.<sup>1</sup>
- Limited data on the epidemiology of upper extremity injuries presenting to the ED currently exist.
- Recent data show the incidence of shoulder injury is 190 injuries per 100,000 persons per year.<sup>2</sup>
- Traumatic shoulder injuries account for 17 percent of upper extremity injuries presenting to EDs. The most common type of injuries seen are fractures (29 percent), strains/sprains (16 percent), and dislocations (5 percent).<sup>2</sup>
- Shoulder injuries are sustained as a result of many scenarios such as participation in sports, accidental trauma sustained in the home and at work, overuse injuries, and motor vehicle accidents.
- Shoulder injuries can be categorized as acute and nonacute.
  - Acute shoulder injuries include traumatic instability, acromioclavicular (AC) and sternoclavicular (SC) joint injury, proximal humerus fractures, scapular fractures, and clavicle fractures.
  - Anterior and anteroinferior instability account for more than 90 percent of shoulder dislocations.
  - Nonacute shoulder injuries include impingement, rotator cuff tendinopathy and tear, biceps tendinopathy and tear, multidirectional instability, and labrum tears.
- It is comprised of three bones and four articulations (Figure 1.1).
  - Three bones:
    - Clavicle, scapula, and humerus.
    - The acromion is an extension from the spine of the scapula and forms a roof over the shoulder joint.
      - A type I acromion has a flat undersurface.
      - A type II acromion has a downward curve and decreased angle of inclination.
      - A type III acromion has a hooked appearance with further decreased angle of inclination.
    - The proximal humerus has four main parts:
      - Humeral head
      - Greater tuberosity
      - Lesser tuberosity
      - Metaphyseal portion of the shaft
  - Four articulations:
    - SC, AC, glenohumeral, and scapulothoracic.
    - The SC joint is the only true articulation between the upper extremity and the axial skeleton.
    - The scapulothoracic articulation is the interface between the scapula and the thorax and does not represent a true joint.
- The glenoid labrum is composed of dense fibrocartilage and increases the surface area of the glenohumeral joint to deepen the socket and provide stability for the joint.
- The muscles of the shoulder attach to the scapula, clavicle, and humerus (Figures 1.2 and 1.3).

## Anatomical Considerations/ Pathophysiology

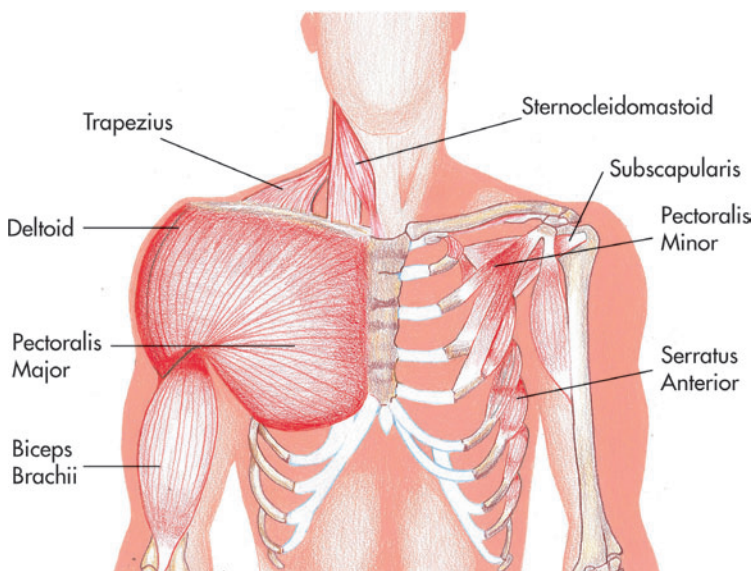
2

- The shoulder is the most mobile joint in the body.

## Shoulder



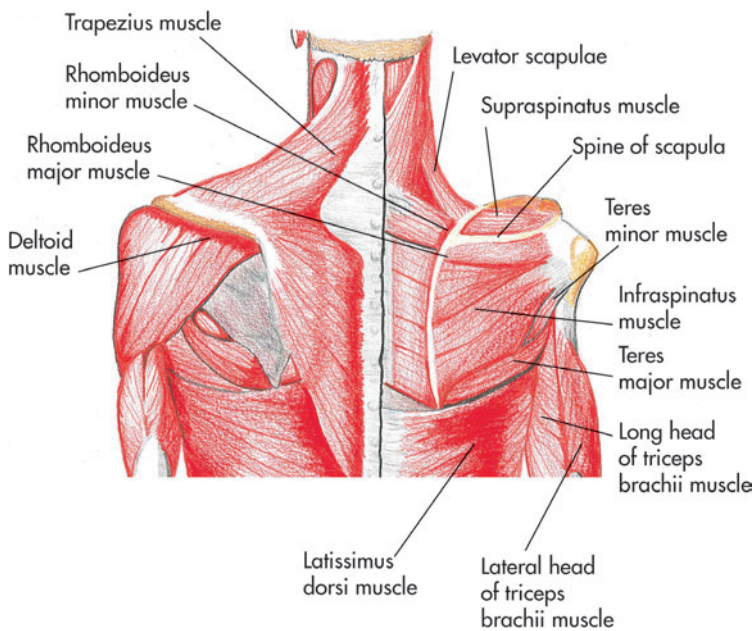
**Figure 1.1.** Bony anatomy of the shoulder.



**Figure 1.2.** Anterior shoulder muscular anatomy.

- The deltoid muscle provides primary motor power at the glenohumeral joint.
  - It functions in elevation, forward flexion, abduction, and extension of the shoulder.
  - It is innervated by the axillary nerve.
- The rotator cuff comprises four muscles and provides dynamic stability to the glenohumeral joint:
  - Supraspinatus
  - Infraspinatus
  - Teres Minor
  - Subscapularis

## Sports Medicine for the Emergency Physician: A Practical Handbook



**Figure 1.3.** Posterior shoulder muscular anatomy.

- The supraspinatus functions in shoulder elevation and is innervated by the suprascapular nerve.
  - The infraspinatus functions in external rotation of the shoulder and is innervated by the suprascapular nerve.
  - The teres minor functions in external rotation of the shoulder and is innervated by the axillary nerve.
  - The subscapularis functions in internal rotation of the shoulder and is innervated by the subscapular nerve.
  - Other muscles involved with motion at the shoulder include the following:
    - Pectoralis major
    - Latissimus dorsi
    - Biceps brachii
    - Trapezius
    - Rhomboids
    - Levator scapulae
    - Serratus anterior
- degenerative or inflammatory conditions, or causative factors from other regions in the body.
- In adolescents and young adults traumatic injury and poor postural habits are common causes of shoulder complaints.
  - In older patients shoulder complaints can be attributed to overuse in sports or occupational activities, and to wear of articular and periarticular structures.
  - The history should include the site and type of pain, duration, and time of occurrence.
    - Referred pain occurs in the subacromial bursa.
    - Pain from a rotator cuff tear is commonly referred to the proximal upper arm or felt diffusely in the deltoid.
    - AC symptoms are usually located directly over the joint.
    - Night pain is common in rotator cuff injury and in advanced impingement syndromes like calcific tendinitis.
  - Some patients cannot precisely describe the location of pain and radiation into the arm, trunk, and head can occur.
    - It's important to distinguish shoulder disorders from neurovascular disorders such as distal compression neuropathies, thoracic outlet syndrome, cervical rib

### Focused History and Physical Exam

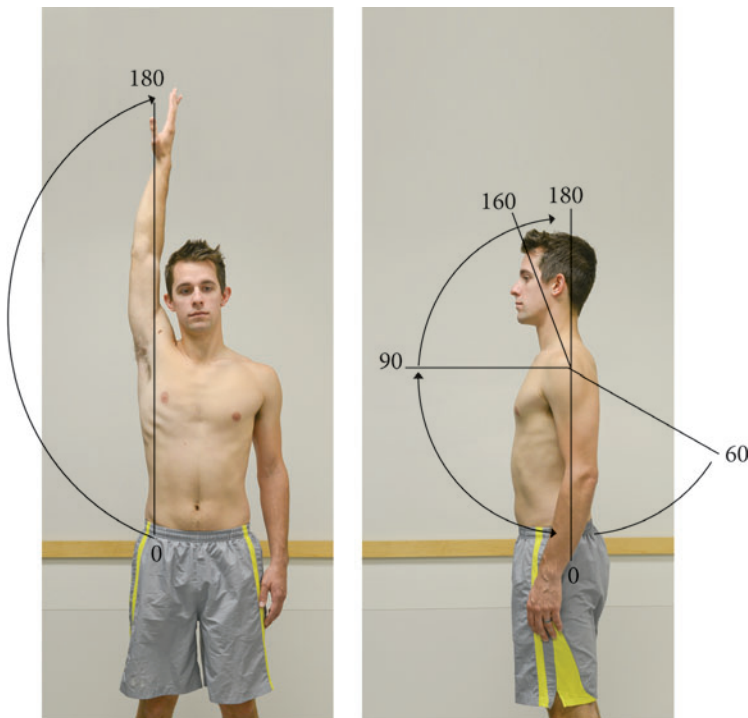
- Assessment of shoulder complaints requires taking a focused history.
- Important historical features regarding the onset of pain or dysfunction include eliciting a traumatic mechanism of injury,

## Shoulder

syndrome, cervical spine disorders or injury, and other disorders such as splenic rupture and cardiopulmonary disease.

- Additional historical features include:
  - Right or left handedness
  - Occupation, hobby, or sports participation
  - Chronic or recurrent symptoms
  - Previous diagnosis
  - Past surgical interventions
  - Treatments the patient has tried, including the use of oral and topical medications, heat and cold therapy, and a sling or brace
  - Restrictions with range of motion
  - Difficulty with activities of daily living
    - Males will commonly note difficulty reaching a wallet in their back pants pocket, putting on a shirt, or fastening a seatbelt.
    - Women will commonly note difficulty hooking a bra or doing their hair.<sup>3</sup>
- Physical examination of the shoulder should be systematic and include inspection, palpation, range of motion, special maneuvers, and neurovascular evaluation.
- Inspection begins with looking for joint symmetry, alignment, bony deformities, swelling, scars, ecchymosis, atrophy, and hypertrophy.
  - Note any abnormalities on observation of the shoulder, shoulder girdle, and related musculature anteriorly and posteriorly.
  - Identify any swelling, deformity, muscle atrophy, hypertrophy, fasciculations, or abnormal positioning.
  - Observe for swelling of the joint capsule anteriorly or a bulge in the subacromial bursa.
  - Examine the entire upper extremity for color change, skin alteration, and abnormal bony contours.
- Palpate bony structures of the shoulder first, then palpate any areas of pain.
  - While palpating, watch for any areas of tenderness or swelling.
  - First palpate the SC joint medially and follow the clavicle laterally with your fingers.
    - Posteriorly palpate the spine of the scapula and follow it laterally and upward until you reach the anterior tip of the acromion.
    - With your index finger on top of the acromion, posterior to the tip, press your thumb medially and find the slightly elevated ridge that marks the distal edge of the clavicle at the AC joint.
    - Medially and a short step down, palpate the coracoid process of the scapula.
    - On the lateral aspect of the humerus, palpate the greater tubercle, where the rotator cuff muscles insert.
    - Move your fingers just medial to the greater tubercle to palpate the biceps tendon within the intertubercular groove.
    - To palpate the subacromial bursa, subdeltoid bursa, and the rotator cuff muscles, extend the humerus to bring these structures anterior to the acromion.
      - Supraspinatus lies directly under the acromion.
      - Infraspinatus sits posterior to the supraspinatus.
      - Teres minor is found posterior and inferior to the supraspinatus.
      - Subscapularis inserts anteriorly and is not palpable.
      - Looking down on the shoulder from above, assess for swelling in the fibrous articular capsule and synovial membrane.
      - Palpate the capsule and synovial membrane under the anterior and posterior acromion.
- Range of motion should be assessed starting with active range of motion, then with passive range of motion if any active restrictions are noted.
  - All range of motion assumes a neutral-zero method, where 0° is represented by the patient's arm hanging down at his or her side.
  - The shoulder girdle is capable of moving in six directions: flexion, extension, abduction, adduction, and internal and external rotation.
  - Stand in front of the patient and observe for smooth movement.
  - Note muscle strength for each direction.

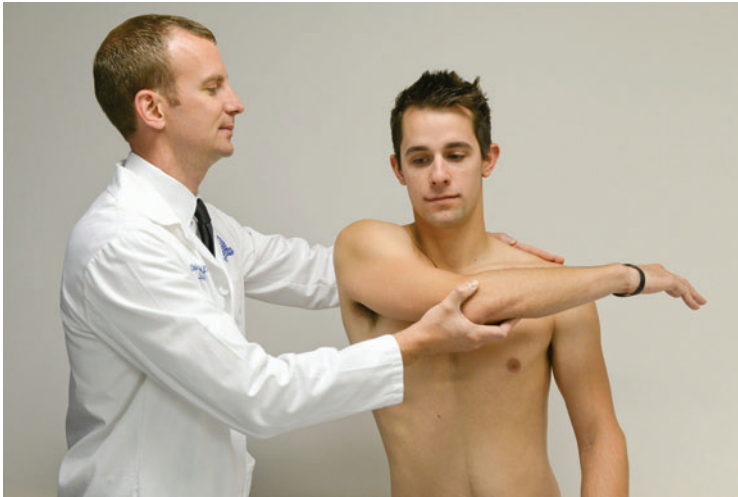## Sports Medicine for the Emergency Physician: A Practical Handbook



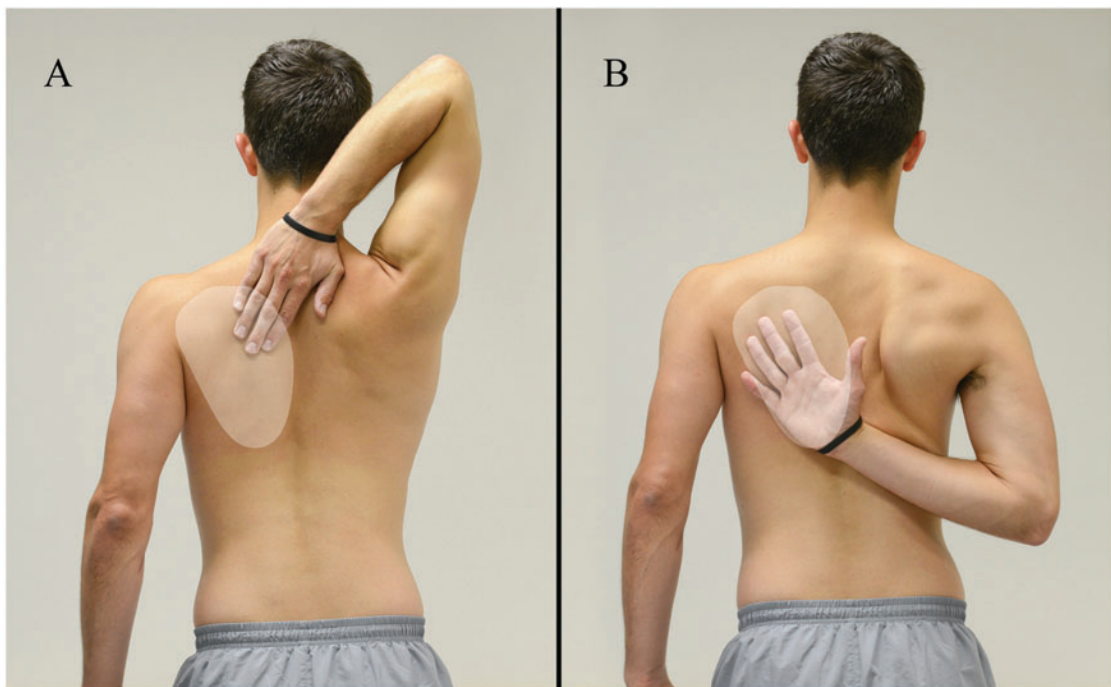
**Figure 1.4.** Forward elevation, extension and abduction.

- For flexion or forward elevation (Figure 1.4), ask the patient to raise the arms in front and overhead.
  - Normal range of motion is from 0° to 160–180°.
- For extension (Figure 1.4), ask the patient to raise the arms behind the body.
  - Normal range of motion is 0–60°.
- To test abduction (Figure 1.4), ask the patient to raise the arms above the head.
  - Normal range of motion is 0–180°.
  - Glenohumeral range of motion is 0–90°.
  - Scapulothoracic motion is 90–150° of abduction.
  - Both glenohumeral and scapulothoracic motion account for the last 30° of motion.
  - Painful arc is present when the patient experiences pain between 60° and 120° of active abduction.
- For adduction, ask the patient to cross the arm in front of the body.
  - Normally, a patient should be able to touch the opposite shoulder.
- To test internal rotation, ask the patient to place one hand behind the back and touch the shoulder blade.
  - Identify the highest spinous process the patient can touch.
  - Normally patients will be able to reach T7–T10. T9 is near the lower border of the scapula and serves as a good landmark.
  - Often patients will be able to reach higher with the nondominant hand.
- For external rotation, ask the patient to raise the arm to shoulder level, bend the elbow, and raise the forearm to the ceiling.
  - Normal range of motion is up to 90°.
- There are more than twenty special maneuvers for testing shoulder function but not all are well studied. Commonly performed maneuvers are described later.
  - The *crossover test* (Figure 1.5) is used to assess for injury to the AC joint.
    - While palpating the AC joint, adduct the patient's arm across the chest.

## Shoulder



**Figure 1.5.** Crossover test for AC joint disorders.

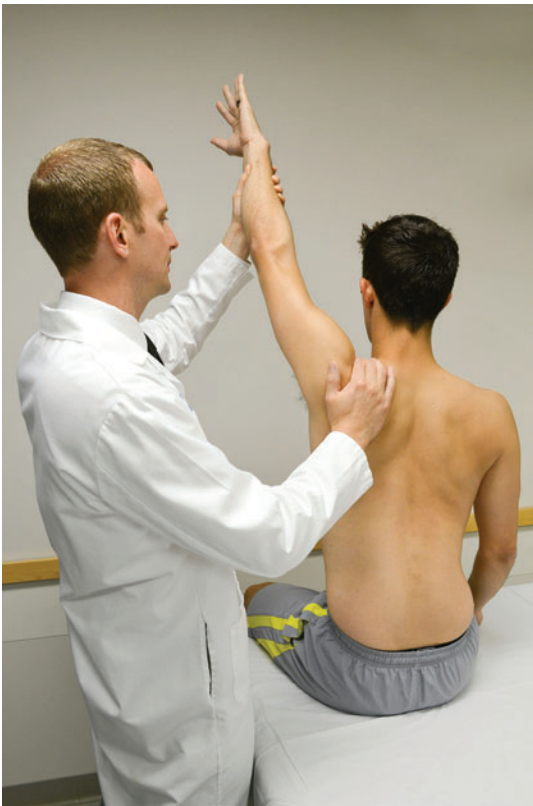

**Figure 1.6 A and B.** Apley scratch test.

- A positive test will elicit pain at the AC joint.
- *Apley scratch test* (Figures 1.6 A and B) assesses overall shoulder rotation.
  - Ask the patient to reach behind the head and touch the top of the scapula (Figure 1.6A). This tests abduction and external rotation.
  - Next, ask the patient to reach behind the back and touch the bottom of the scapula (Figure 1.6B). This tests adduction and internal rotation.
  - Difficulty with either of these motions is suggestive of a rotator cuff disorder, adhesive capsulitis, or glenohumeral osteoarthritis.

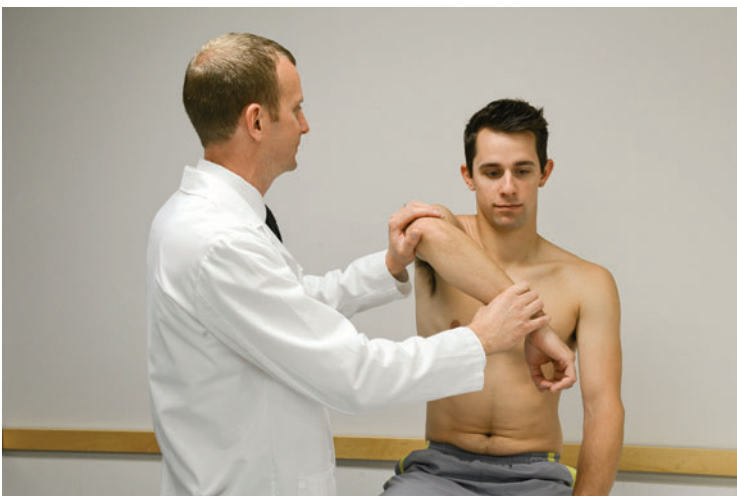## Sports Medicine for the Emergency Physician: A Practical Handbook

- *Neer's impingement sign* (Figure 1.7) evaluates for dynamic subacromial impingement, including constriction, inflammation, or injury to the rotator cuff.
  - Stabilize the scapula with one hand and with the other hand internally rotate



**Figure 1.7.** Neer's impingement sign.

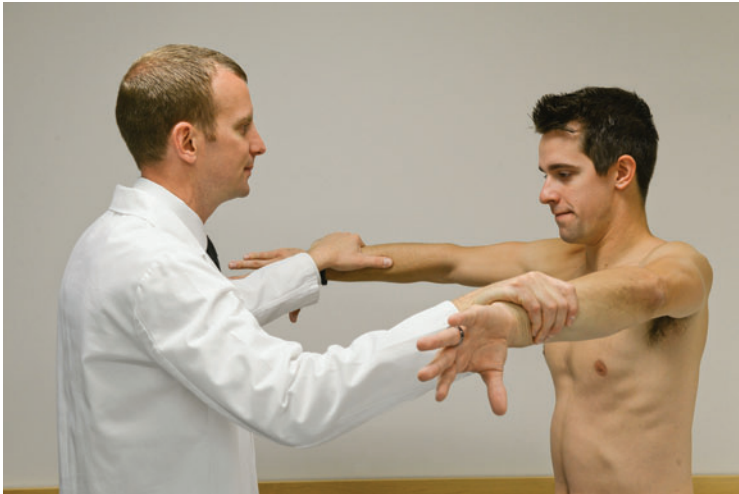- the shoulder and then move the patient's arm into forward flexion.
  - A positive test will elicit pain as the shoulder is placed into forward flexion as the greater tuberosity of the humerus rotates below the acromion.
- *Hawkins–Kennedy impingement sign* (Figure 1.8) is similar to Neer's impingement sign and also evaluates for subacromial impingement.
  - Flex the patient's shoulder and elbow to 90° with the palm facing down. Place one hand on the patient's forearm and another on the arm and rotate the arm internally.
  - A positive test will elicit pain as the greater tuberosity is compressed against the coracoacromial ligament.
- The *empty can test* (Figure 1.9) evaluates supraspinatus strength.
  - Elevate the arms to 90° in the scapular plane and internally rotate them at the shoulder so the thumbs are facing down. Ask the patient to resist as you press down on the arms.
  - A positive test is indicated by weakness.
- The *infraspinatus test* (Figure 1.10) can help you evaluate for an infraspinatus disorder or tear.
  - With the arms at his or her side, ask the patient to bend the elbows to 90° and



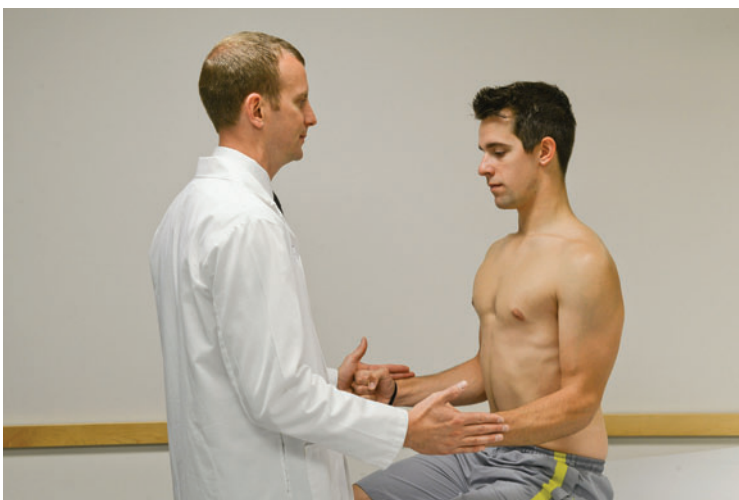**Figure 1.8.** Hawkins–Kennedy impingement sign.



## Shoulder



**Figure 1.9.** Empty can test.



**Figure 1.10.** Infraspinatus test.

- provide resistance as he or she presses the forearms outward.
  - A positive test is indicated by weakness.
- The *lift-off test* (Figure 1.11) tests for subscapularis strength.
  - Ask the patient to place the arm in internal rotation with the dorsum of the hand on the back as you provide resistance.
  - A patient with a subscapularis tear will be unable to perform this maneuver.
- The *drop arm test* (Figures 1.12A and B) is a good test in evaluating for a supraspinatus tear.
  - With the patient seated, passively abduct the arm to 120° (Figure 1.12A). Ask the patient to hold the arm in that position without support and then slowly bring it to his or her side (Figure 1.12B).
  - A positive test is indicated by failure to maintain an abducted position or a sudden drop of the arm as the patient brings the arms back down towards the side.
- *Speed's test* (Figure 1.13) is an indicator for biceps injury.
  - Ask the patient to elevate the arm in supination and 60° of forward flexion, and to maintain this position as you

## Sports Medicine for the Emergency Physician: A Practical Handbook

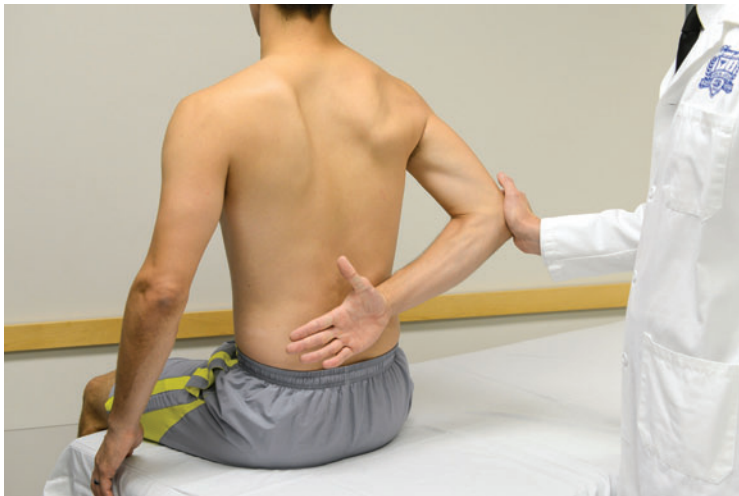

Figure 1.11. Lift-off test.

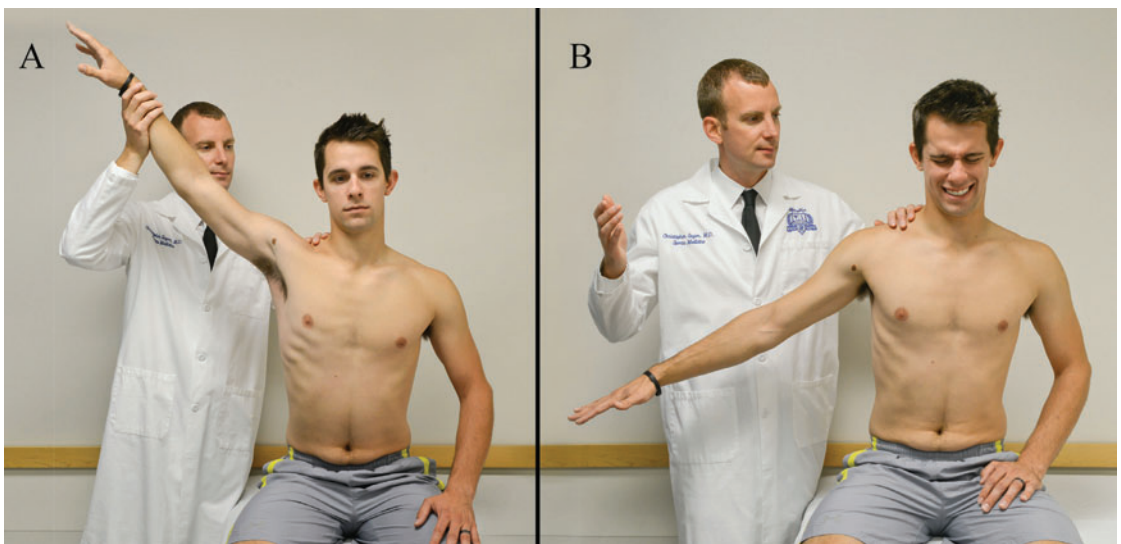


Figure 1.12A and B. Drop arm test.

- provide downward pressure on the arm.
- Asymmetrical strength and pain in the region of the bicipital groove suggests a disorder of the long head of the biceps tendon.
- *Popeye sign* (Figure 1.14) indicates a proximal long head of the biceps tendon rupture.
  - Ask the patient to abduct the arm to 90° and flex at the elbow (i.e., ask them to flex the muscles).
- This sign is present when there is a large bump in the area of the biceps muscle belly.
- It may only be obvious when compared to the contralateral side.
- *O'Brien's active compression test* (Figures 1.15a and b) is used to detect labral pathology.
  - Stand behind the patient and ask him or her to flex the affected arm to 90°, adduct 15° medially, and internally rotate the arm.