PART

I

# Plain Radiography

# 1

# Plain Radiography of the Upper Extremity in Adults

*Kenny Banh and Gregory W. Hendey*

Plain radiography remains the imaging study of choice for most applications in the upper extremity. Far and away, the most common indication for plain radiography in the upper extremity is acute trauma. The shoulder, humerus, elbow, forearm, wrist, and hand are common radiographic series that are useful in diagnosing an acute fracture. Other imaging modalities such as CT, ultrasound, and MRI are not generally indicated in acute trauma, but have an important role in diagnosing soft tissue pathology.

Another common indication for plain radiography of the upper extremity is the search for a foreign body in a wound. Plain films are an excellent modality for the detection of common, dense foreign bodies encountered in wounds, such as glass and rock, but they are much less sensitive in the detection of plastic or organic materials (1). Other imaging modalities such as CT, ultrasound, and MRI are superior for the detection of organic and plastic foreign bodies (2). The principles of using plain films for foreign body detection are similar regardless of the location in the body and are not discussed in further detail here.

In this chapter, the upper extremity is divided into three sections: 1) the shoulder, 2) the elbow and forearm, and 3) the wrist and hand. Within each section, the indications, diagnostic capabilities, and pitfalls are discussed, followed by images of important pathological findings.

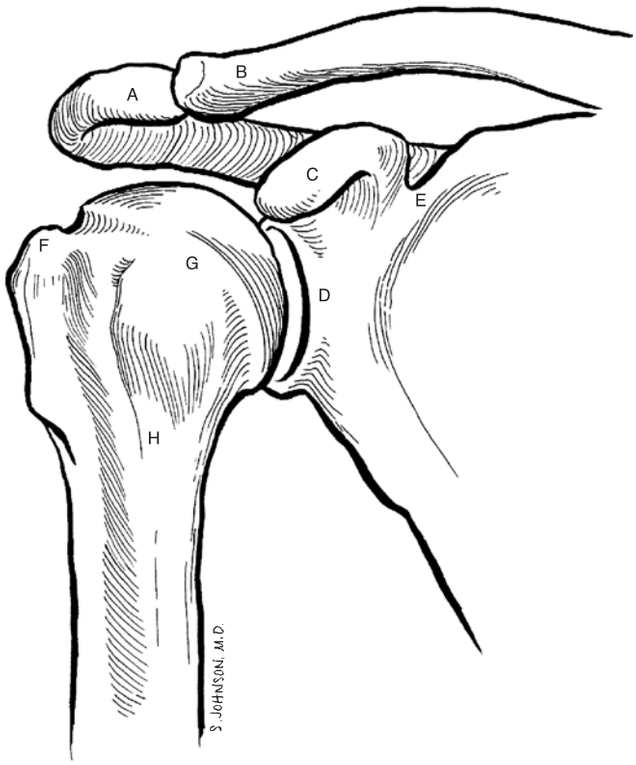


Anterior Shoulder. A = Acromion, B = Clavicle, C = Coracoid process, D = Neck of scapula, E = Scapular notch, F = Greater tuberosity, G = Anatomical neck, H = Surgical neck

## THE SHOULDER

### Indications

The main indication for plain radiography of the shoulder is acute trauma. There are a number of acute injuries that may be discovered on plain radiography after acute trauma, including fractures of the clavicle, scapula, and humerus, as well as shoulder (glenohumeral) dislocation or acromioclavicular (AC) separation. Although many patients may present with subacute or chronic nontraumatic pain, the utility of plain films in that setting is extremely low. In the setting of chronic, nontraumatic shoulder pain, plain films may reveal changes consistent with calcific tendonitis or degenerative arthritis, but it is not necessary to diagnose such conditions in the emergency setting.

Several studies have focused on the issue of whether all patients with shoulder dislocation require both prereduction and postreduction radiographs (3). Some support an approach of selective radiography, ordering prereduction films for first-time dislocations and those with a blunt traumatic mechanism

of injury, and postreduction films for those with a fracture-dislocation. It is also important to order radiographs whenever the physician is uncertain of joint position, whether dislocated or reduced. Therefore, it may be appropriate to manage a patient with a recurrent dislocation by an atraumatic mechanism without any radiographs, when the physician is clinically certain of the dislocation and the reduction.

### Diagnostic Capabilities

In most settings, if the plain films do not reveal a pathological finding, no further imaging is necessary. MRI is an important modality in diagnosing ligamentous injury (e.g., rotator cuff tear), but is rarely indicated in the emergency setting.

With the possible exception of the scapula, most fractures of the shoulder girdle are readily apparent on standard plain films, without the need for specialized views or advanced imaging. The shoulder is no exception to the general rule of plain films that at least two views are necessary for adequate evaluation. The two most common views in a "shoulder series" include the anteroposterior (AP) and the lateral or "Y" scapula view. Other views that are sometimes helpful include the axillary and apical oblique views. In the axillary view, the film cassette is placed superior to the shoulder and the beam is directed up into the axilla, with the humerus in a slightly abducted position. In the apical oblique, the cassette is posterior to the shoulder and the beam is directed from a position 45 degrees superior to the shoulder. The point of both additional views is to enhance visualization of the glenoid and its articulation with the humeral head. These views may be particularly helpful in diagnosing a posterior shoulder dislocation or a subtle glenoid fracture.

Another specific radiographic series that is sometimes used is the AC view with and without weights. Although the intent of these views is to augment the physician's ability to diagnose an AC separation, they are not recommended for the following reasons: 1) the views might occasionally distinguish a second- from a first-degree separation, but that difference has little clinical relevance because both are treated conservatively; and 2) third-degree AC separations are usually obvious clinically and radiographically, without the need for weights or additional views.

### Imaging Pitfalls/Limitations

Although most acute shoulder injuries may be adequately evaluated using a standard two-view shoulder series, posterior shoulder dislocation can be surprisingly subtle and is notoriously difficult to diagnose. When posterior dislocation is suspected based on the history, physical, or standard radiographic views, additional specialized views such as the axillary and apical oblique can be very helpful. Most radiographic views of the shoulder may be obtained even when the injured patient has limited mobility, but the axillary view does require some degree of abduction and may be difficult.

### Clinical Images

Following are examples of common and important findings in plain radiography of the shoulder:

1. Clavicle fracture (fx)
2. AC separation
3. Anterior shoulder dislocation
4. Posterior dislocation (AP)
5. Posterior dislocation (lateral scapula)
6. Luxatio erecta
7. Bankart fx
8. Hill-Sachs deformity
9. Humeral head fracture

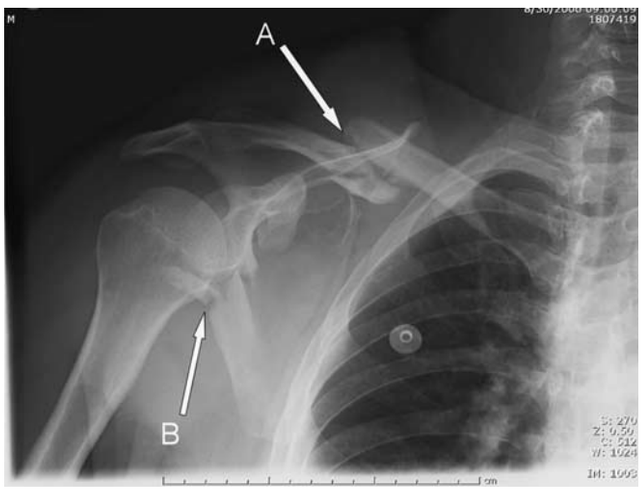


Figure 1.1. Clavicle fractures (A) are often described by location, with the clavicle divided into thirds: proximal, middle, or distal. Note the scapular fracture (B) as well.

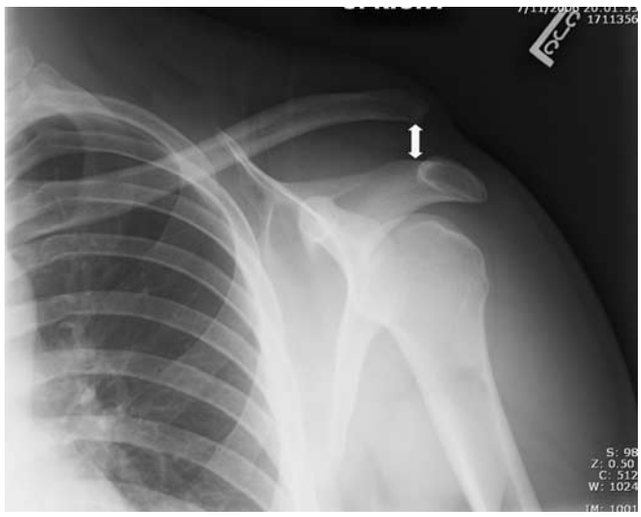

Figure 1.2. AC separation is commonly referred to as a "separated shoulder" and can be classified as grade 1 (AC ligament and coracoclavicular [CC] ligaments intact, radiographically normal), grade 2 (AC ligament disrupted, CC ligament intact), or grade 3 (both ligaments disrupted, resulting in a separation of the acromion and clavicle greater than half the width of the clavicle).

Figure 1.3. The large majority of shoulder dislocations are anterior, and the large majority of anterior dislocations are subcoracoid, as demonstrated in this AP view.

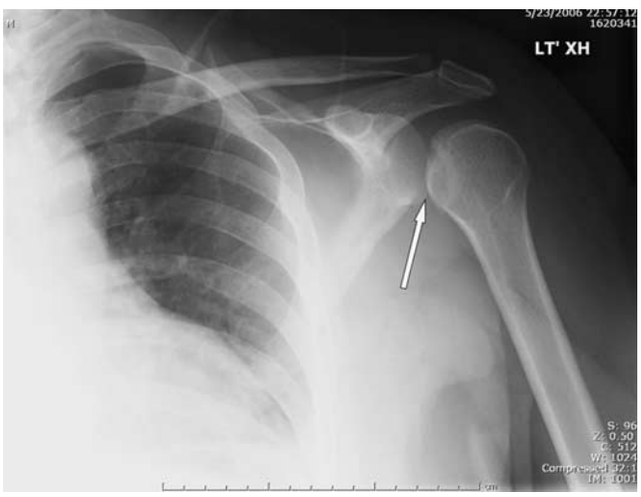


Figure 1.4. Posterior shoulder dislocation is uncommon and is difficult to diagnose on a single AP radiograph. Although it is not obvious in this single view, there are some hints that suggest posterior dislocation. The humeral head is abnormally rounded due to internal rotation (light bulb sign), and the normal overlap between the humeral head and glenoid is absent.

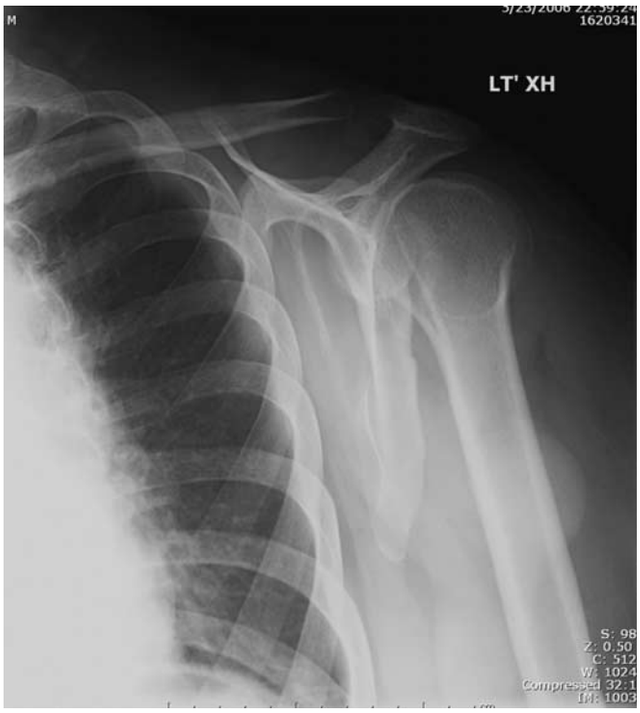


Figure 1.5. Posterior shoulder dislocation is clearly evident on this lateral scapula view, while it was much more subtle on the preceding AP view (see Fig. 1.4). This illustrates the importance of obtaining a second view such as the lateral scapula view or axillary view.


Figure 1.6. Luxatio erecta is the rarest of shoulder dislocations in which the humeral head is displaced inferiorly while the arm is in an abducted or overhead position.

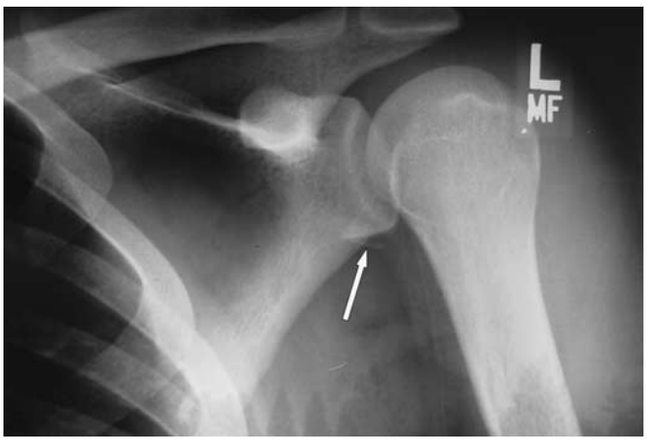


Figure 1.7. Although radiographically subtle, the Bankart fracture is a small avulsion of the inferior rim of the glenoid. The loss of the glenoid labrum destabilizes the glenohumeral joint and nearly assures recurrent dislocations.


Figure 1.8. The Hill-Sachs deformity is a compression fracture of the superolateral aspect of the humeral head and is commonly noted in recurrent shoulder dislocations. It is believed to occur when the humeral head is resting against the inferior rim of the glenoid while dislocated.

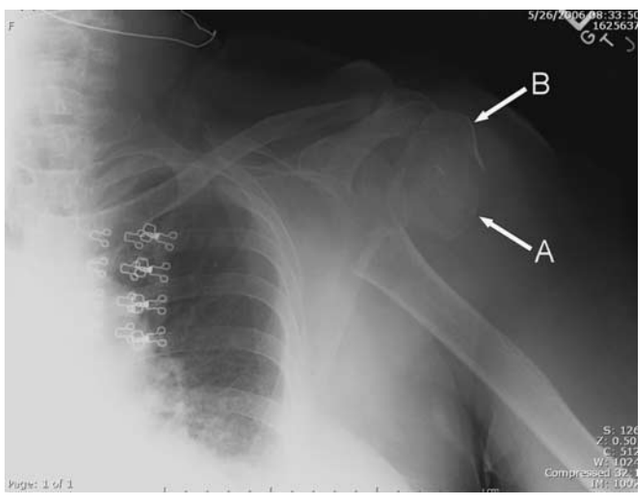


Figure 1.9. Humeral head fracture often occurs across the surgical neck (A) but may also occur at the anatomical neck (B).

## THE ELBOW AND FOREARM

### Indications

Similar to the shoulder, the most common use of elbow and forearm plain radiography is in the setting of acute trauma. There are numerous fractures and dislocations that can be easily visualized with plain films. Chronic pain in these areas is often secondary to subacute repetitive injuries of the soft tissue such as epicondylitis or bursitis. Many of these soft tissue diseases such as lateral "tennis elbow" and medial "golfer's elbow" epicondylitis are easily diagnosed on clinical exam and generally require no imaging at all. Plain films may reveal such soft tissue pathologies as foreign bodies and subcutaneous air.

No well-established clinical decision rules exist for the imaging of elbows and forearms in the setting of acute trauma. Patients with full range of flexion-extension and supination-pronation of the elbow and no bony point tenderness rarely have a fracture, and they generally do not require imaging (4). Midshaft forearm fractures are usually clinically apparent, and deformity, swelling, and/or limited range of motion are all indications for obtaining radiographs.

### Diagnostic Capabilities

In most cases, if no pathology is found in the plain films of the forearm or elbow, no further imaging is required. Although obvious fractures are easily visualized on plain film, some fractures leave more subtle findings. Radiographs of the elbow in particular may yield important indirect findings. The elbow joint is surrounded by two fat pads, an anterior one lying within the coronoid fossa and a slightly larger posterior fat pad located within the olecranon fossa. In normal circumstances, the posterior fat pad cannot be visualized on plain films, but a traumatic joint effusion may elevate the posterior fat pad enough to be visualized on a 90-degree lateral radiograph. The anterior fat pad is normally visualized as a thin stripe on lateral radiographs, but joint effusions may cause it to bulge out to form a "sail sign" (5). Traumatic joint effusions are sensitive signs of an intraarticular elbow fracture (6).

### Imaging Pitfalls/Limitations

The two standard views of the elbow are the AP view and the lateral view with the elbow flexed 90 degrees. The majority of fractures can be identified with these two views, but occasionally supplementary views may be obtained to identify certain parts of the elbow and forearm. The lateral and medial oblique views allow easier identification of their respective epicondylar fractures. The capitellum view is a cephalad-oriented lateral view that exposes the radial head and radiocapitellar articulation. The axial olecranon is shot with a supinated and flexed forearm and isolates the olecranon in a longitudinal plane. Despite these supplementary views, pediatric fractures sometimes reveal no findings on plain radiographs, so a low threshold must be kept to conservatively splint or use more advanced imaging techniques.

### Clinical Images

Following are examples of common and important findings in plain radiography of the elbow and forearm:

10. Posterior fat pad
11. Radiocapitellar line
12. Elbow dislocation, posterior
13. Monteggia fracture
14. Galeazzi fracture (AP)
15. Galeazzi fracture (lateral)


Figure 1.10. Subtle soft tissue findings such as this posterior fat pad (A) and sail sign (B) are markers for fractures that should not be dismissed.

Figure 1.11. A radiocapitellar line is drawn through the radius and should bisect the capitellum regardless of the position of the elbow.


Figure 1.12. A common joint dislocation, only overshadowed in numbers by shoulder and interphalangeal dislocations, most elbow dislocations occur during hyperextension. The majority are posterior and are obvious clinically and radiographically.


Figure 1.13. Monteggia fractures/dislocations are fractures of the proximal ulna with an anterior dislocation of the proximal radius. These injuries are usually caused by rotational forces, and the dislocation may not be obvious. Drawing a radiocapitellar line aids in making the diagnosis as it demonstrates the misalignment.


Figure 1.14. Galeazzi fractures or Piedmont fracture is a fracture of the distal third of the radius with dislocation of the distal ulna from the carpal joints. This is the exact opposite of a Monteggia fracture and is also caused by rotational forces in the forearm, although more distal.


Figure 1.15. Often mistaken for a simple distal radius fracture on AP radiograph, the dislocation is clearly evident on a lateral forearm or wrist.

## THE WRIST AND HAND

### Indications

As with the rest of the upper extremity, the major indication for imaging of the wrist and hand is in the setting of acute trauma. It is one of the most difficult areas to differentiate between soft tissue and skeletal injury on history and physical examination alone. Imaging is necessary even with obvious fractures because the extent of the fracture, displacement, angulation, and articular involvement are important to determine if the patient needs closed reduction in the ED or immediate orthopedic referral for possible open reduction and surgical fixation.

There are still settings where imaging of the hand and wrist is not indicated. Carpal tunnel disease and rheumatologic and gouty disorders are chronic diseases that usually do not involve acute trauma and can be diagnosed based on a good history and physical exam alone.

### Diagnostic Capabilities

Besides searching for acute bony fractures and dislocations, plain films can reveal other important pathology. In the setting of high-pressure injection injuries to the hand, subcutaneous air is a marker for significant soft tissue injury, and often an indication for surgical exploration. Many carpal dislocations and ligamentous injuries are readily visualized on radiographs of the wrist and hand. Perilunate and lunate dislocations usually result from hyperextension of the wrist and fall on an outstretched hand or "FOOSH" injury. They may be poorly localized on physical exam and films, and a good neurovascular exam, especially of the median nerve, is indicated.

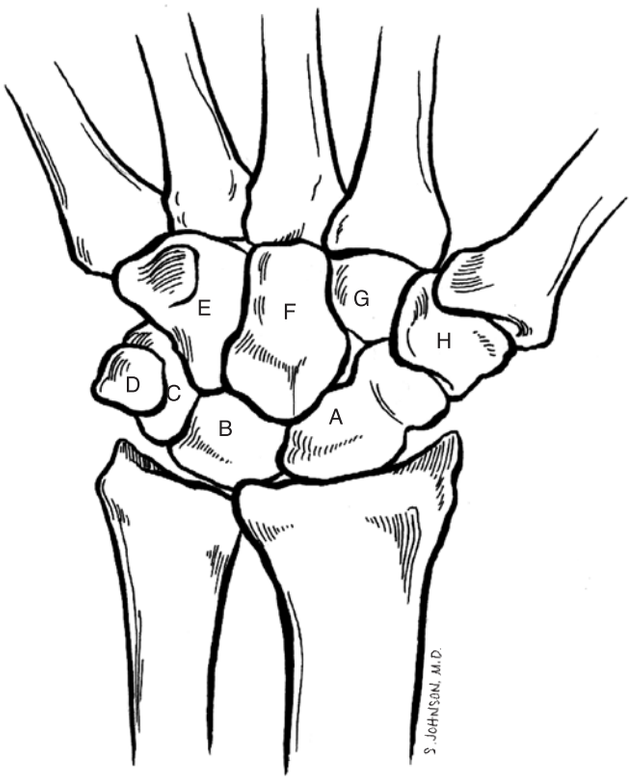


Bones of the Wrist: Palmar View. A = Scaphoid, B = Lunate, C = Triquetrum, D = Pisiform, E = Hamate, F = Capitate, G = Trapezoid, H = Trapezium

### Imaging Pitfalls/Limitations

Because of the size and number of bones, complete radiographic sets of hand and wrist films are often acquired. The minimum standard views of the hand and wrist involve a posterior-anterior, lateral, and pronated oblique. This third view helps assess angulated metacarpal fractures that would normally superimpose on a true lateral. Accessory views of the hand such as the supination oblique or ball catcher's view can help view fractures at the base of the ring and little finger, while a Brewerton view, which dorsally places the hand down and shoots the film at an ulnar oblique angle, allows better visualization of the metacarpal bases. The wrist accessory films include a scaphoid view, a carpal tunnel view that looks at the hook of the hamate and trapezium ridge, and a supination oblique view that isolates the pisiform. These accessory films should be ordered whenever there is localized tenderness or swelling in these areas.

Unlike the proximal upper extremity, fractures in the wrist and hand may not always be readily apparent on plain films. Scaphoid fractures often result from a FOOSH injury. About 10% to 20% of scaphoid fractures have normal radiographs on initial presentation to the ED. Therefore, it is extremely important to not disregard these clinical signs of scaphoid fracture: "anatomical snuff box" tenderness, pain with supination against resistance, and pain with axial compression of the thumb.

More advanced imaging modalities of the wrist and hand such as CT, MRI, and high-resolution ultrasound are much more sensitive for identifying fractures, bone contusions, and ligamentous injury that would be missed on plain radiography (7). Whether advanced imaging is indicated in the emergency department may depend on local resources.

### Clinical Images

Following are examples of common and important findings in plain radiography of the wrist and hand:

16. Colles' fracture (AP)
17. Colles' fracture (lateral)
18. Smith's fracture (AP)
19. Smith's fracture (lateral)
20. Scaphoid fracture
21. Scapholunate dissociation
22. Lunate dislocation (AP)
23. Lunate dislocation (lateral)
24. Perilunate dislocation (AP)
25. Perilunate dislocation (lateral)
26. Boxer's fracture (AP)
27. Boxer's fracture (lateral)
28. Tuft fracture


Figure 1.16. A Colles' fracture occurs at the distal metaphysis of the radius with dorsal displacement and radial length shortening. An extremely common injury pattern also seen in FOOSH injuries, the radial head is shortened, creating a disruption of the normally almost linear continuation of the radial and ulnar carpal surfaces.


Figure 1.17. The dorsal displacement is evident on the lateral radiograph, and proper reduction needs to restore this alignment.


Figure 1.18 (*left*). A Smith's fracture, also known as a reverse Colles' fracture, is a distal radius fracture with volar instead of dorsal displacement of the hand. Usually caused by direct blows to the dorsum of the hand, these fractures often need eventual surgical reduction.

Figure 1.19 (*right*). Sometimes referred to as a "garden spade" deformity, the lateral view differentiates this type of fracture from the more common Colles' fracture.


Figure 1.20. Because of the size and number of hand and wrist bones, many subtle fractures are missed on cursory views of plain radiographs. All AP hand views should be checked for smooth carpal arches formed by the distal and proximal bones of the wrist. Evidence of avascular necrosis in scaphoid fractures occurs in the proximal body of the fracture because the blood supply of the scaphoid comes distally from a branch of the radial artery. The arrow denotes a scaphoid fracture.

Figure 1.21. A tight relationship between adjacent carpal bones and the distal radius and ulna should be observed as well. The loss of this alignment or widening of the space, as seen here between the scaphoid and lunate bones, is a sign of joint disruption, from fracture, dislocation, or joint instability. A widening of greater than 4 mm is abnormal and known as the "Terry-Thomas sign" or rotary subluxation of the scaphoid. The scaphoid rotates away and has a "signet ring" appearance at times.


Figure 1.22. Lunate dislocations are the most common dislocations of the wrist and often occur from FOOSH injuries. They are significant injuries involving a volar displacement and angulation of the lunate bone. Notice how the carpal arches are no longer clearly seen.